MICRO Imaging of the Brain's Microvasculature

Sagar Buch, Ph.D.

Department of Radiology

Wayne State University

WAYNE STATE UNIVERSITY

Vascular Imaging

- Imaging the microvasculature is key to unlocking the etiology of many neurodegenerative diseases including: dementia, hypertension, multiple sclerosis, Parkinson's disease, stroke, and traumatic brain injury (TBI)

- It is difficult to detect small vessels (<250μ) using conventional MRI due to the lack of contrast and/or imaging resolution

Microvascular In-vivo Contrast Revealed Origins: MICRO

- **MICRO** enables superior microvasculature imaging by:

  1. Using ultra-small superparamagnetic iron oxides (**USPIO**) to induce an increase in susceptibility in both ***arteries and veins***
  2. Employing high spatial resolution to increase small vessel visibility
  3. Utilizing SWI processing to further enhance the vascular signal loss

- We use low dose *Ferumoxytol*, an FDA approved USPIO agent for treating anemia, to accomplish these goals.

Process of obtaining Susceptibility weighted imaging (SWI) data

$$\varphi_M(\vec{r}) = \begin{cases} 1 - \frac{|\varphi(\vec{r})|}{\pi}, & if -\pi < \varphi < 0 \\ 1, & else. \end{cases}$$

$$SWI = mag \cdot [\varphi_M(\vec{r})]^n$$

where, n is generally 4

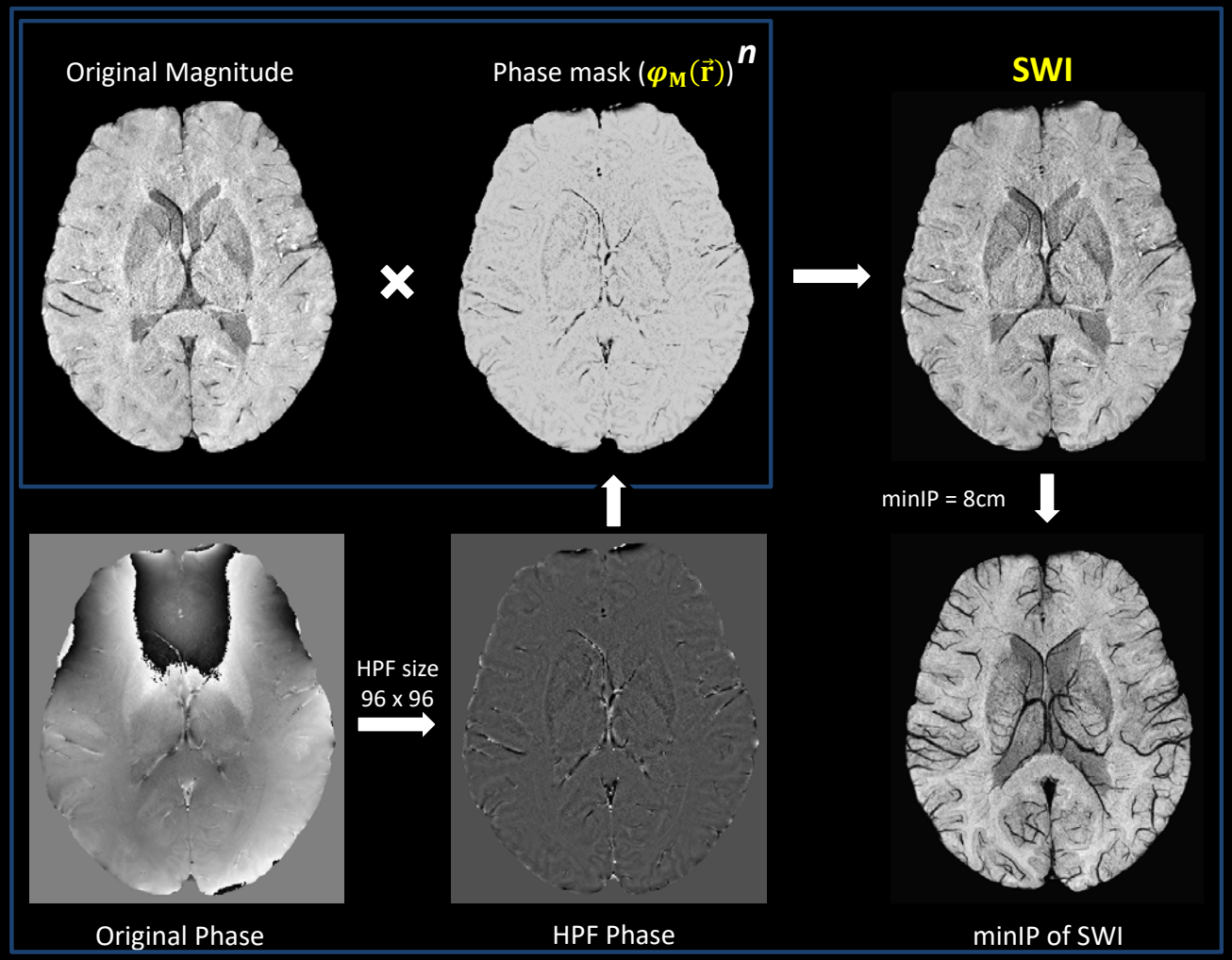

Process of obtaining Susceptibility weighted imaging (SWI) data

$$\varphi_M(\vec{r}) = \begin{cases} 1 - \frac{|\varphi(\vec{r})|}{\pi}, & if \quad 0 < \varphi < \pi \\ 1, & else. \end{cases}$$

$$SWI = mag \cdot [\varphi_M(\vec{r})]^n$$

where, n is generally 4

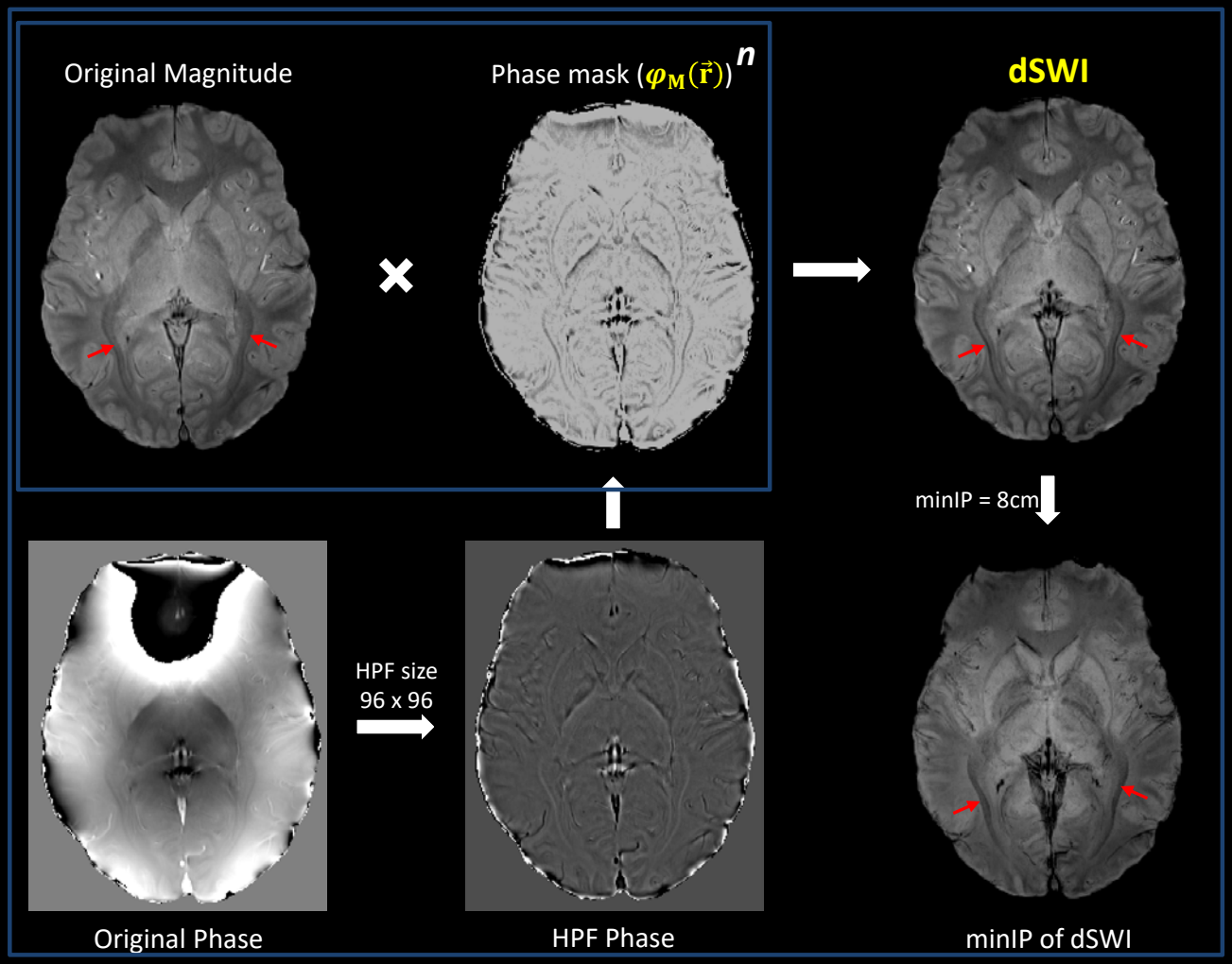

Jella, P. K., Y. Chen, W. Tu, S. Makam, S. Beckius, E. Hamtaei, CC-T. Hsu, and E. M. Haacke. "American Journal of Neuroradiology 42, no. 2 (2021): 285-287.

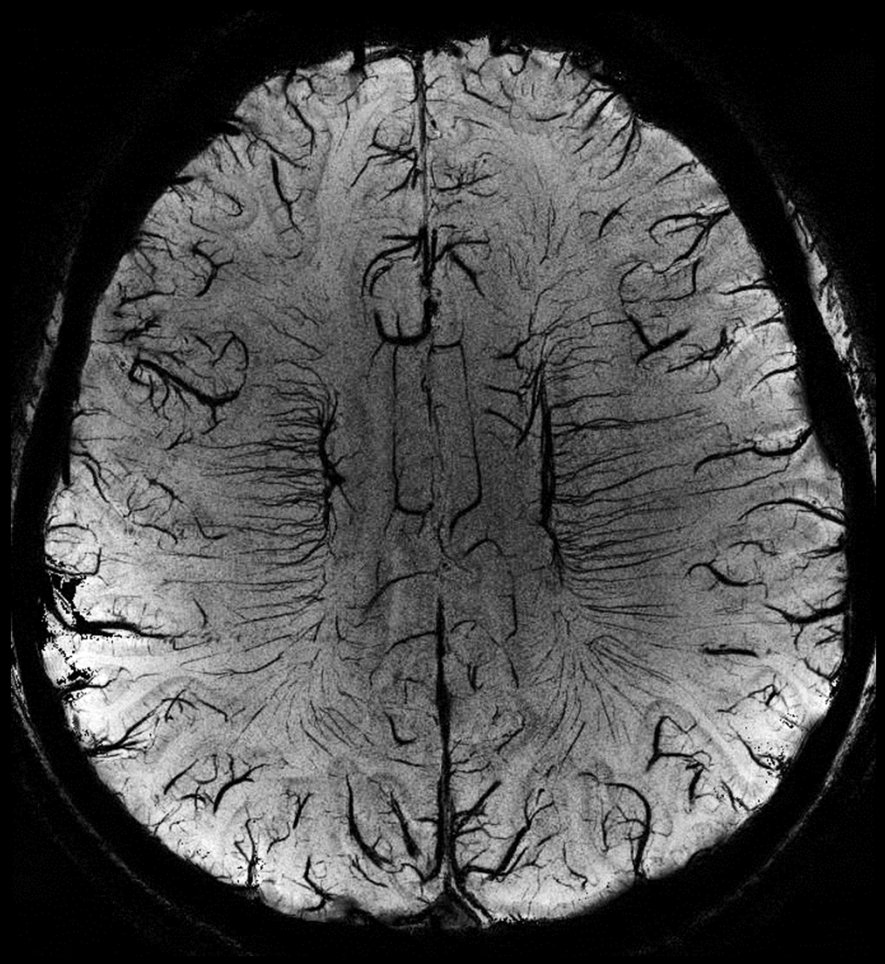

7T SWI non-contrast data

215x215x1000µm^3
TE = 16ms, TR = 45ms, FA = 25°
8 slice mIP

Image courtesy of Yulin Ge, NYU

Imaging properties of Ferumoxytol and GdDTPA

$$\frac{1}{T_{1eff}} = \frac{1}{T_1} + \alpha[c]$$

Feature	Ferumoxytol	Gd-DTPA (Magnevist)
Basic element	Iron oxide	Gadolinium(III)
Molecular composition	Iron oxide coated with semisynthetic carbohydrate	Gadolinium chelated with diethylenetriamine penta-acetic acid
Relaxometric properties at 1.5 T/mM per s, 37°C in water	$r_1 = 15$, $r_2 = 89$[107]	$r_1 = 3.3$, $r_2 = 3.9$[108]
Elimination plasma half-life	14 h[109]	1.6 h
Relative size of the particle	Approximately 30 nm[109]	0.357 nm
Permeability to intact BBB	Minimal	Minimal
Typical times to peak enhancement (in brain lesions)	24 h[110]	3.5–25 min[111]
Signal change on T1-weighted sequence	Increased signal (signal decreased at very high concentrations)	Increased signal
Signal change on T2-weighted sequence	Decreased signal	Usually no change
Signal change on T2*-weighted sequence	Decreased signal	Decreased signal if given as a bolus
Distribution	Dynamic phase, blood pool phase, delayed phase (extra and intracellular)	Dynamic phase, extracellular phase
Imaging dose	1–7 mg/kg	0.1 mmol/kg
Excretion	Stored with the body's iron reserve and used in hemopoesis coating with renal and fecal excretion	Renal
Boxed warning	Potential hypersensitivity	Potential NSF

BBB, blood-brain barrier; Gd-DTPA, gadolinium diethylenetriamine penta-acetic acid; NSF: nephrogenic systemic fibrosis.

Toth GB et al., Kidney Int. 2017 Jul;92(1):47-66.

Imaging properties of Ferumoxytol and GdDTPA

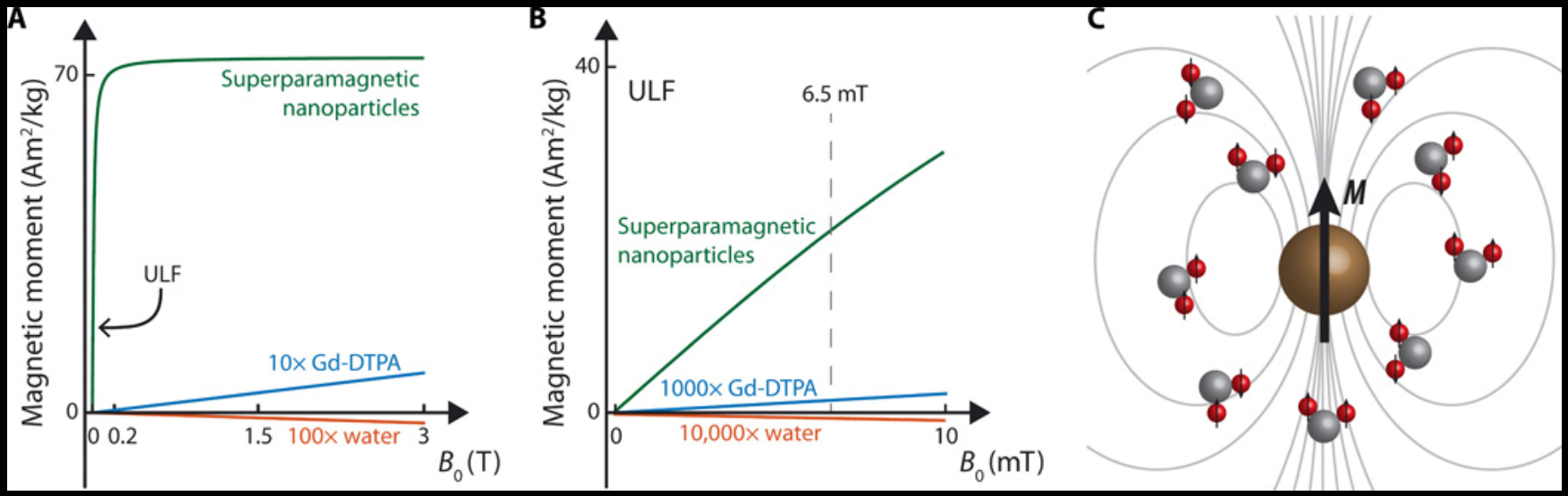

- USPIO is saturated at low fields and so it does not change its properties above roughly 0.5T to 1T.
- USPIOs possess much higher sensitivity than Gadolinium

Waddington et al., Science Advances. 2020: 6(29), eabb0998

Imaging properties of Ferumoxytol and GdDTPA

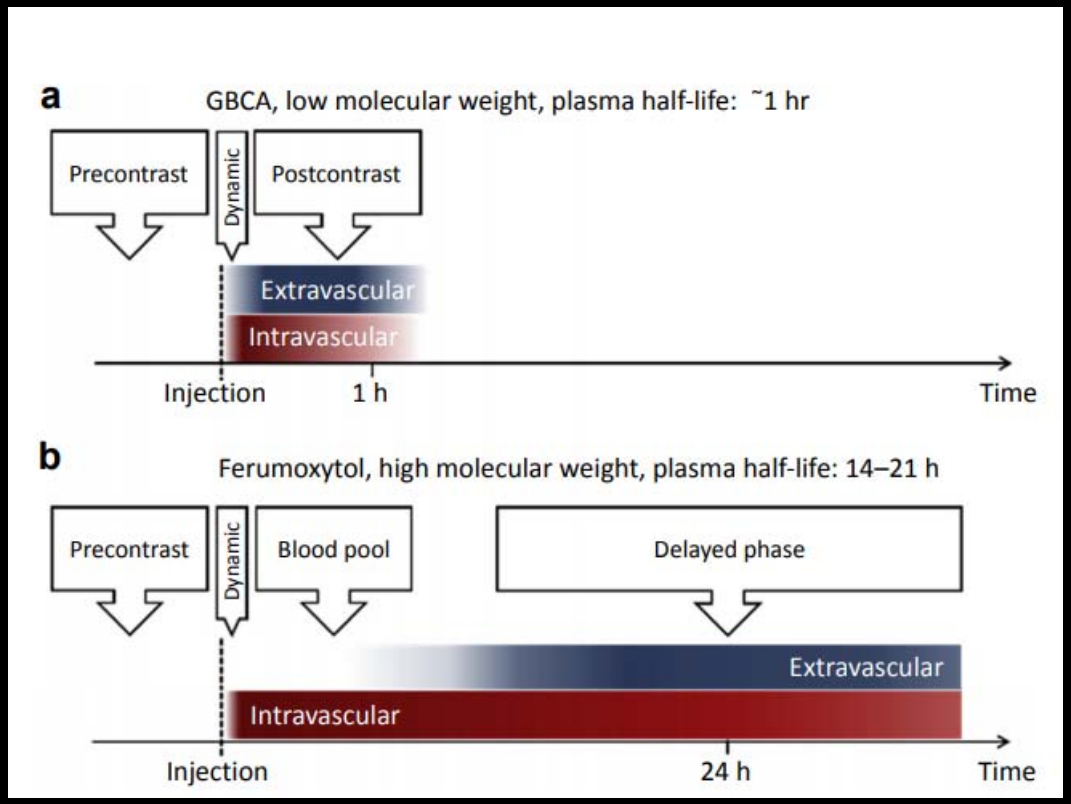

Toth GB et al., Kidney Int. 2017 Jul;92(1):47-66.

Unlike Gd-based CAs, Ferumoxytol has a long intravascular half-life that results in a ***long blood pool phase*** prior to detectable contrast extravasation.

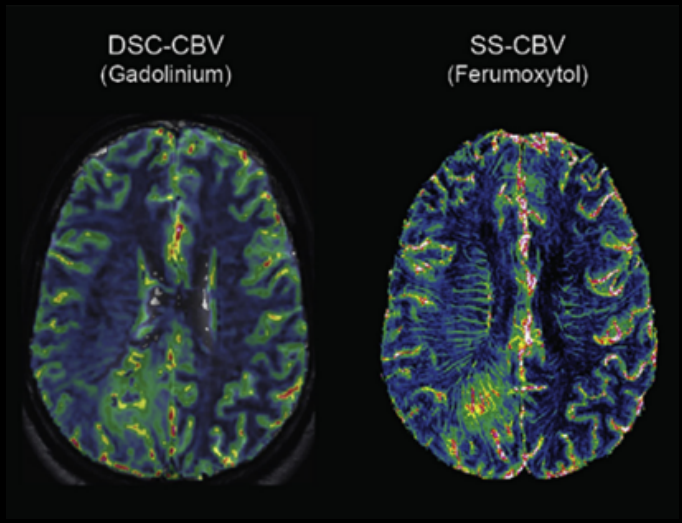

Imaging properties of Ferumoxytol and GdDTPA

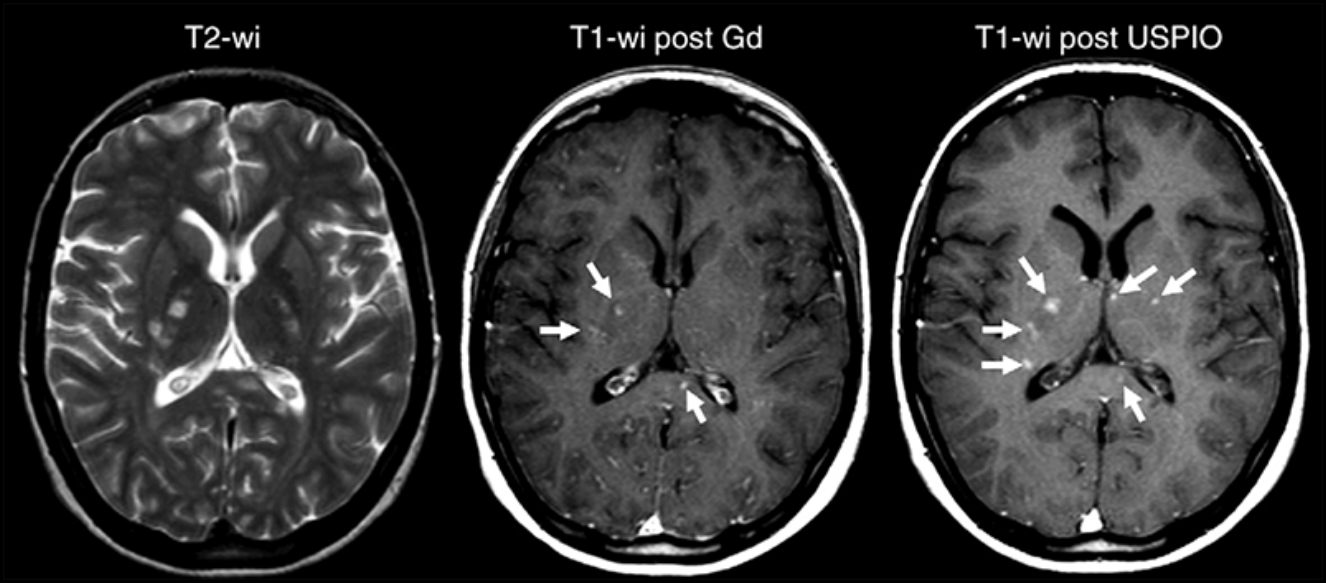

- Ferumoxtran-10 shows the same three lesions along with **three additional active lesions** that enhanced
- Lesions that enhance with both agents may exhibit a more aggressive evolution than those that enhance with only one contrast agent

Wáng YX, Idée JM. Quant Imaging Med Surg. 2017 Feb;7(1):88-122.

Vascular Phase Behavior

Infinite cylinder model

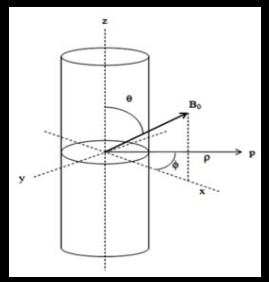

$$\varphi_{External} = \frac{\Delta\chi}{6}\left(3\cos^2\theta - 1\right)B_o$$

At Ferumoxytol dose of 4 mg/kg:
Δχ increases by 1.75 ppm at 3T



Even with a low Ferumoxytol dose of 4mg/kg, we can induce a strong phase behavior in veins as well as arteries, which were invincible on the pre-contrast SWI phase data

Dipole Phase Behavior Leads to T2* Dephasing





Figure is from Chapter 28, Sedlacik J et. al., in Susceptibility Weighted Imaging in MRI. John Wiley 2011

The phase variation that exists outside the vessel or microbleed leads to T_2* dephasing or "the blooming artifact"

SWI capitalizes on the phase to further enhance the presence of small veins.

Ferumoxytol enhanced MRAV on 3T

Pre-contrast

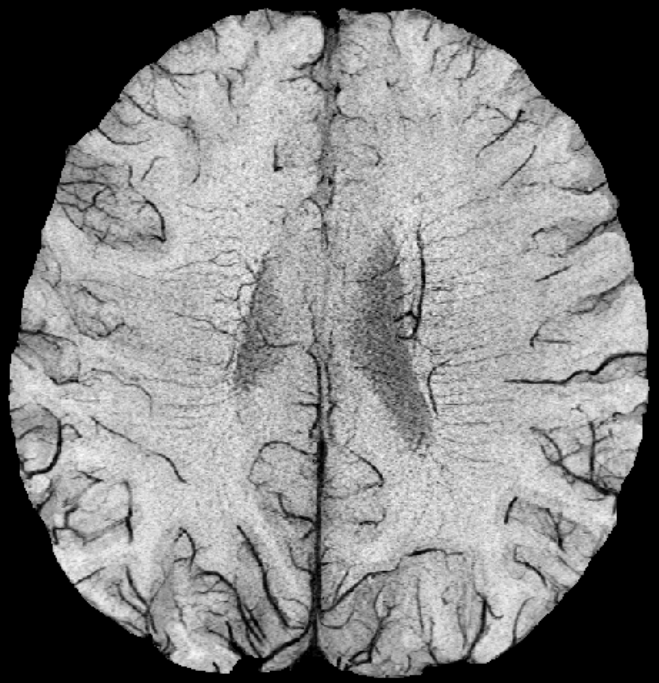

Post-contrast

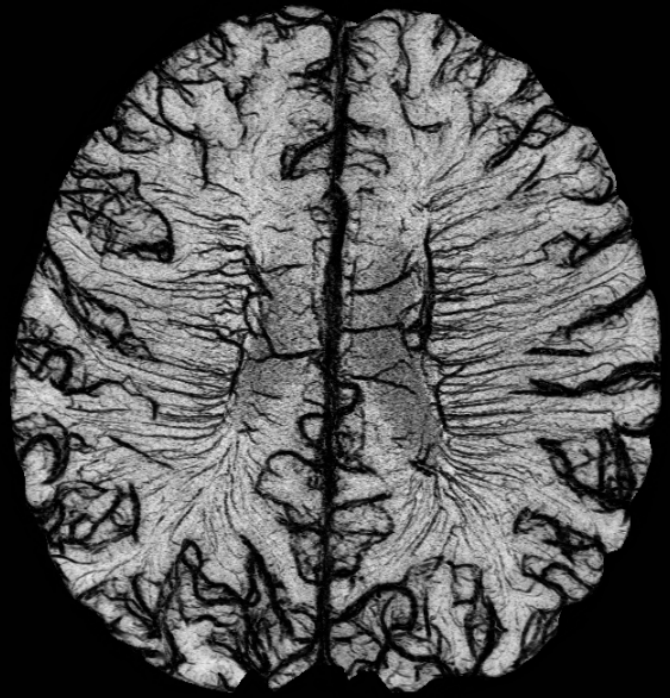

Patient safety

- All subjects with any allergies, low BP, Hemochromatosis or Thalassemia were excluded
- Clinically, it is recommended to administer 7.5 mg/kg in patients who are anemic, over at least 15 min period along with saline
- The maximum dose does not exceed **4 mg/kg** along with 50ml of saline, which was administered over **20 mins**
- All subjects were monitored for 30 min after administering Ferumoxytol
- A trained nurse or Physician is always required to be present during the study at the MR scanner
- To date more than 60 subjects have been scanned without any effects

What is the smallest vessel we can see with MICRO?

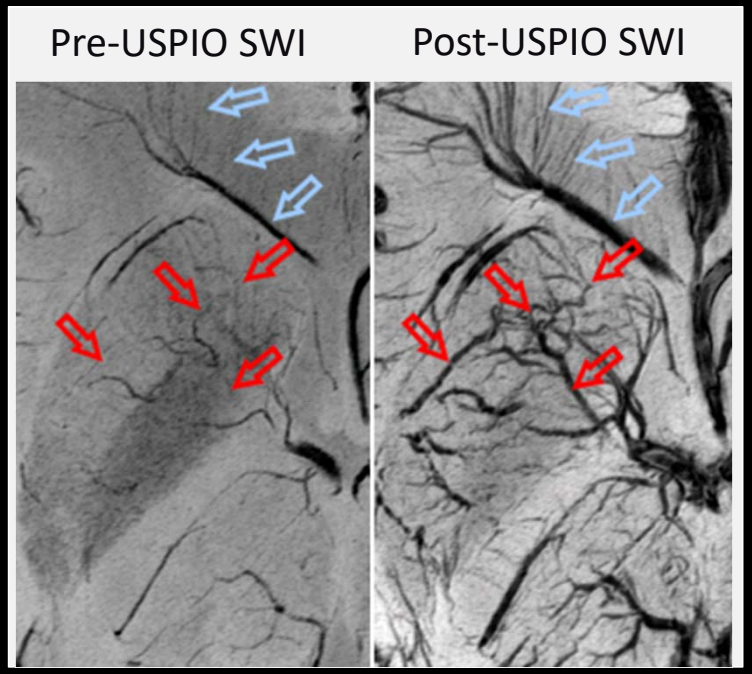

At the same Ferumoxytol dose

- Longer TE and higher resolution improve small artery detection

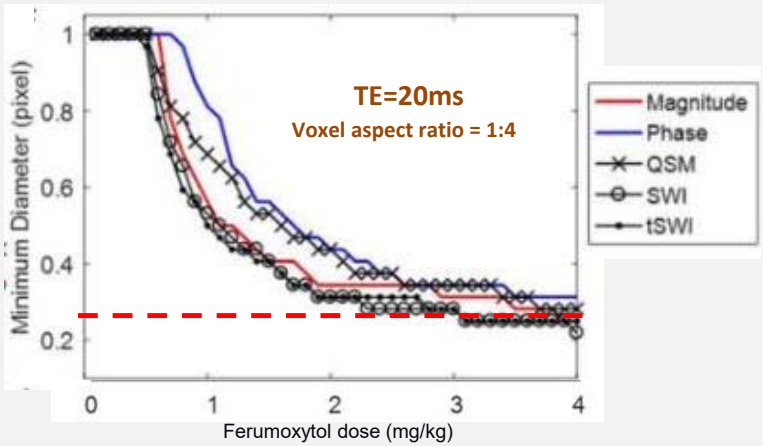

With USPIO, dose, TE, resolution, vessel size all become inter-related and understanding the final response requires careful modeling.

For TE=20ms and a 4mg/kg dose on 7T, we can see vessels as small as one-quarter the voxel size. So, 200um resolution should allow us to see 50um vessels.

Liu S et al, JMRI 2018

MICRO Imaging: Imaging Resolution vs Vessel Visibility

USPIO dose = 4mg/kg of Ferumoxytol; B_0 = 3T

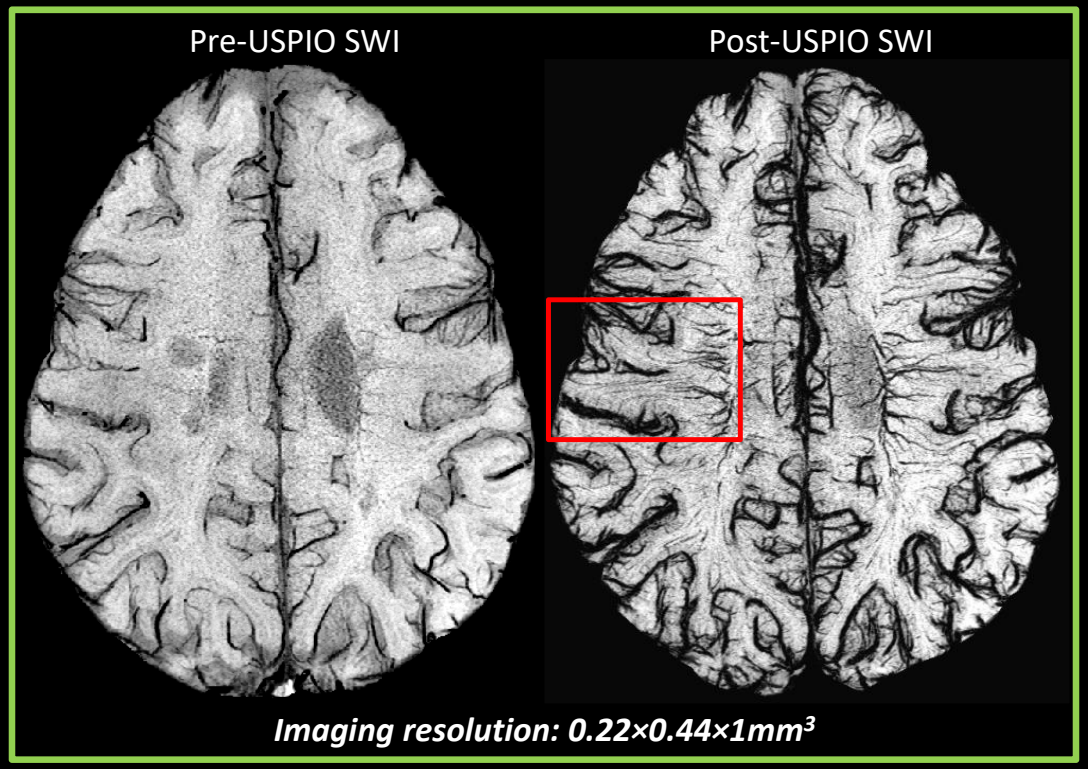

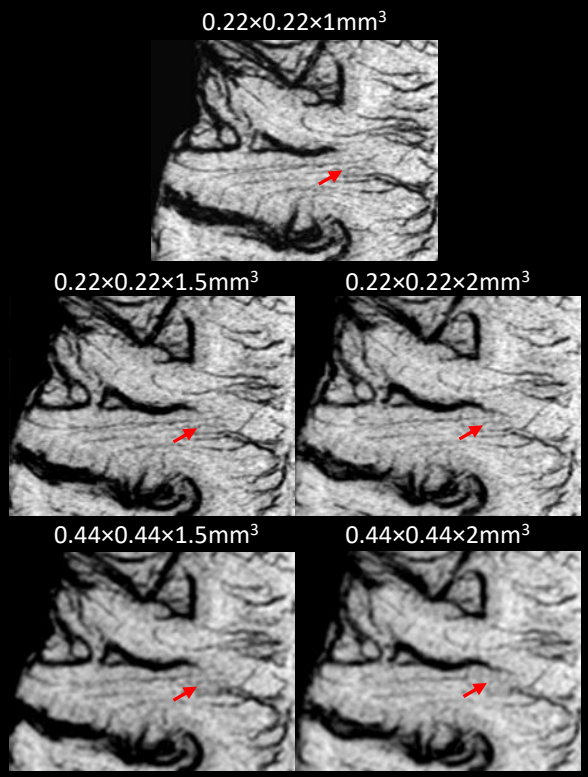

<u>The higher the imaging resolution, the better the detectability of microvasculature</u>

MICRO Imaging: Imaging Resolution vs Vessel Visibility

USPIO dose = 4mg/kg of Ferumoxytol; B_0 = 3T

Pre-USPIO SWI

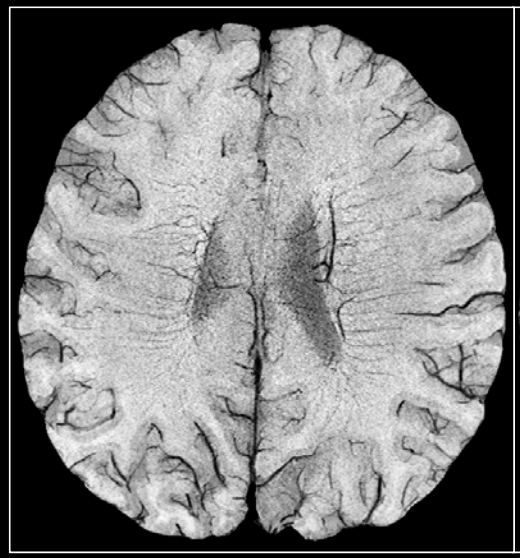

Post-USPIO SWI

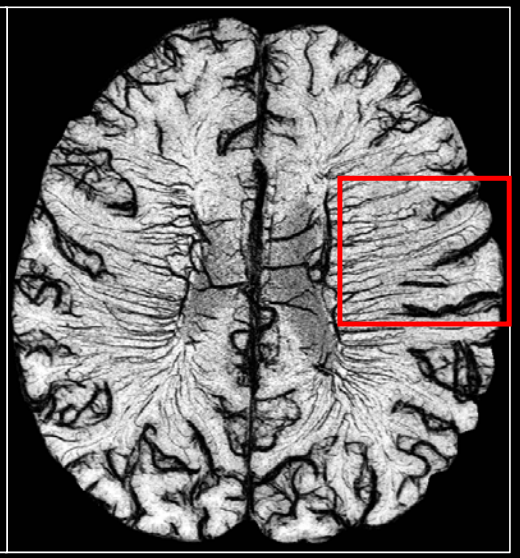

0.22×0.22×1 mm³

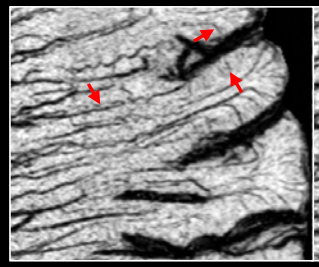

0.22×0.22×1.5 mm³

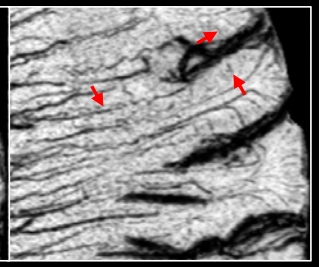

0.22×0.22×2 mm³

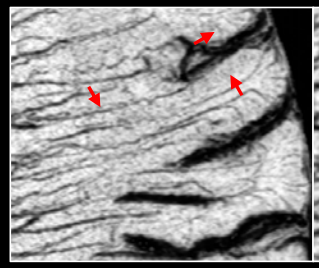

0.44×0.44×1.5 mm³

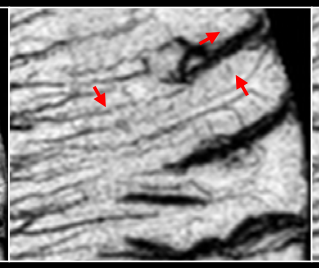

0.44×0.44×2 mm³

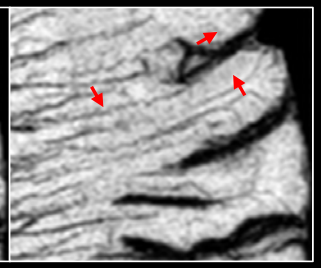

<u>The higher the imaging resolution, the better the detectability of microvasculature</u>

Ferumoxytol enhanced MRAV on 7T

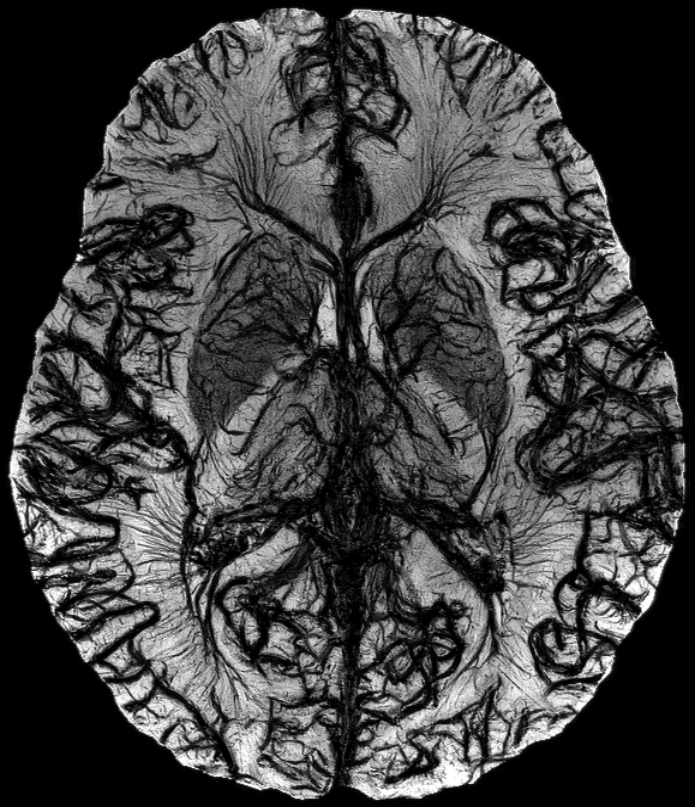

Image courtesy of Yulin Ge and NYU.

3T versus 7T MICRO Imaging

- Given the saturation effects of Ferumoxytol, one could in theory use MICRO at any of 1.5T, 3T and 7T field strengths

- But, high fields offer a linear increase in SNR

- We can double the in-plane resolution at 7T and *still maintain the same SNR* as at 3T
  - SNR α B_o
  - SNR α $\sqrt{(N_x \times N_y)}$

- From a simple practical standpoint, we can already do very well at 3T as shown here, but we can in-principle do a better job at 7T

Applications of MICRO Imaging: Midbrain Microvasculature

MICRO Protocol for Acquiring USPIO-enhanced SWI on 3T

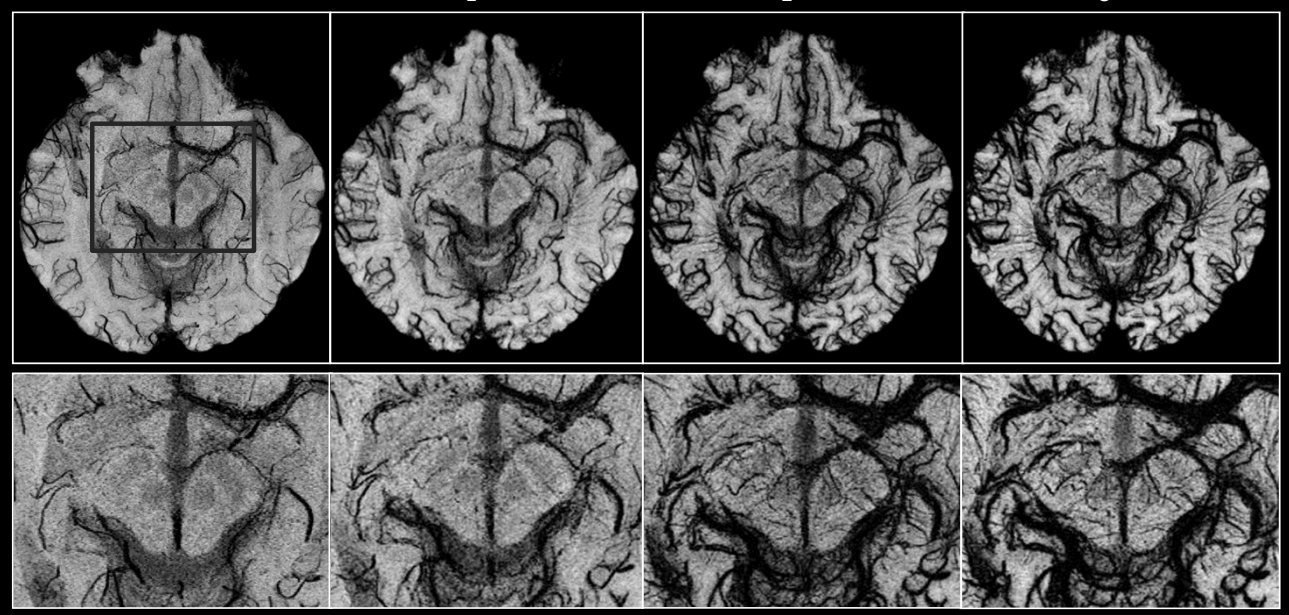

Imaging parameters:

$TE_1/TE_2/TR$ = 7.5/15/27ms, Bandwidth = 180Hz/pxl, number of slices = 96,
flip angle = 12°; voxel size = $0.22\times0.44\times1mm^3$
Acquisition time for each sequence = 11 mins, GRAPPA = 2/36
Final **Ferumoxytol** dose = 4mg/kg, Dose delivery time = 21-23 mins

Buch S, Wang Y, Park MG, et al. **Subvoxel vascular imaging of the midbrain using USPIO-Enhanced MRI.** [published online ahead of print, 2020 Jun 29]. *Neuroimage*. 2020;220:117106.

Mapping the Macro-vasculature: MRA and MRV

Imaging the Arteries and Veins with MICRO

MRA pre-contrast = Arteries

mIP pre-contrast = Veins

mIP post-contrast SWI = Arteries + Veins

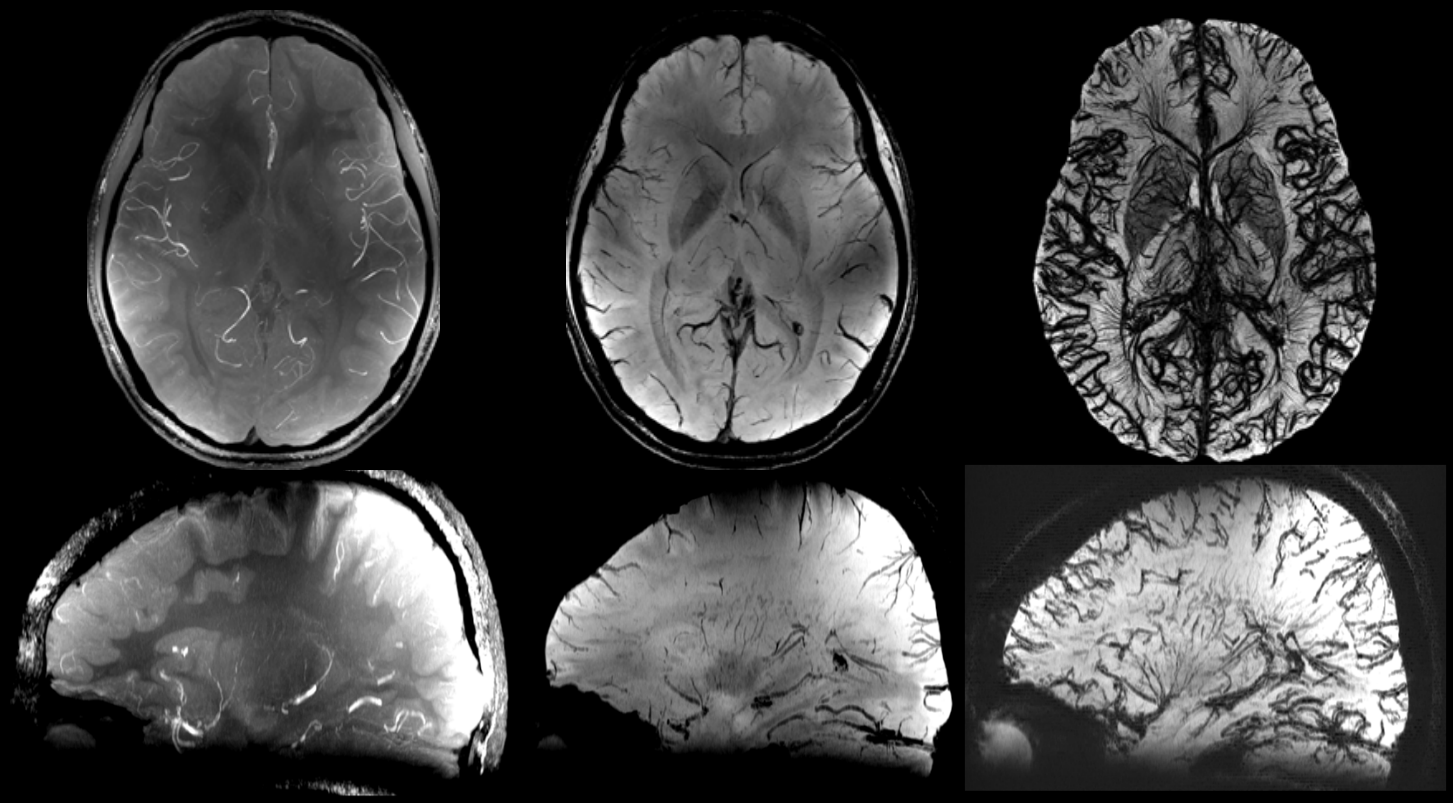

Imaging the Arteries with dual-echo GRE

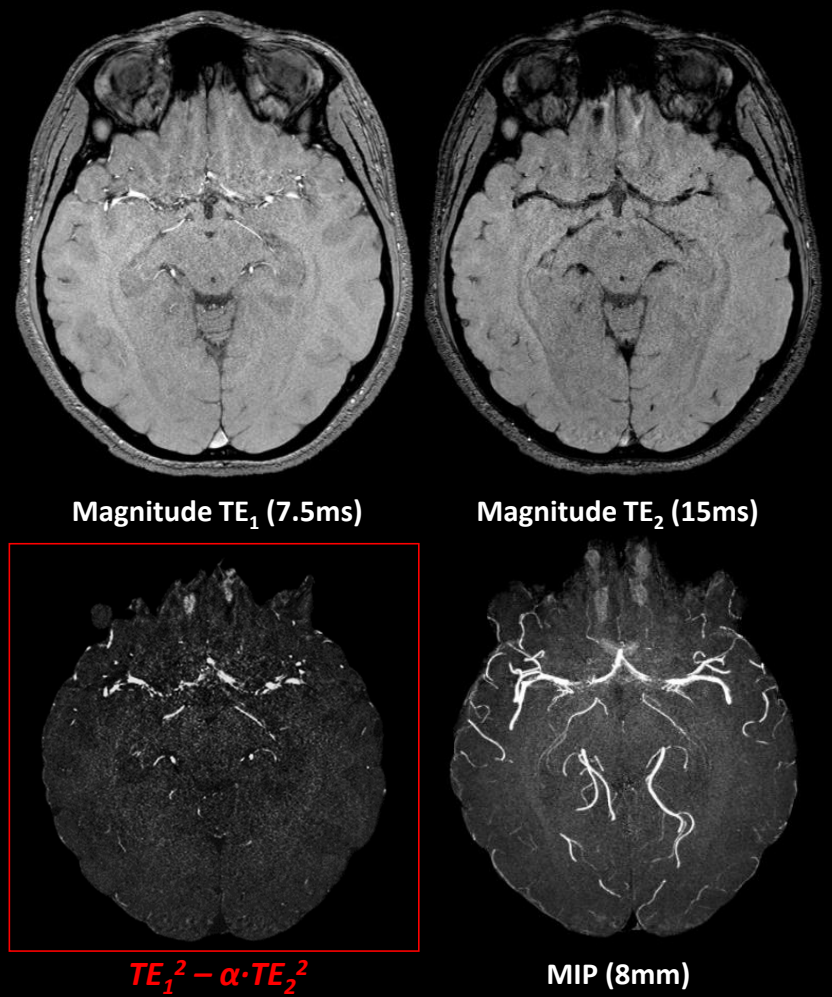

Improved MRA from a ME rephased TE_1 and dephased TE_2

Non-linearly subtracting TE_2 data from TE_1 data yields much more information on the presence of the small arteries

Ye, Y., Hu, J., Wu, D. and Haacke, E.M. (2013), JMRI, 38: 1539-1548.

Magnitude Signal at Different Time Points

Magnitude TE_1

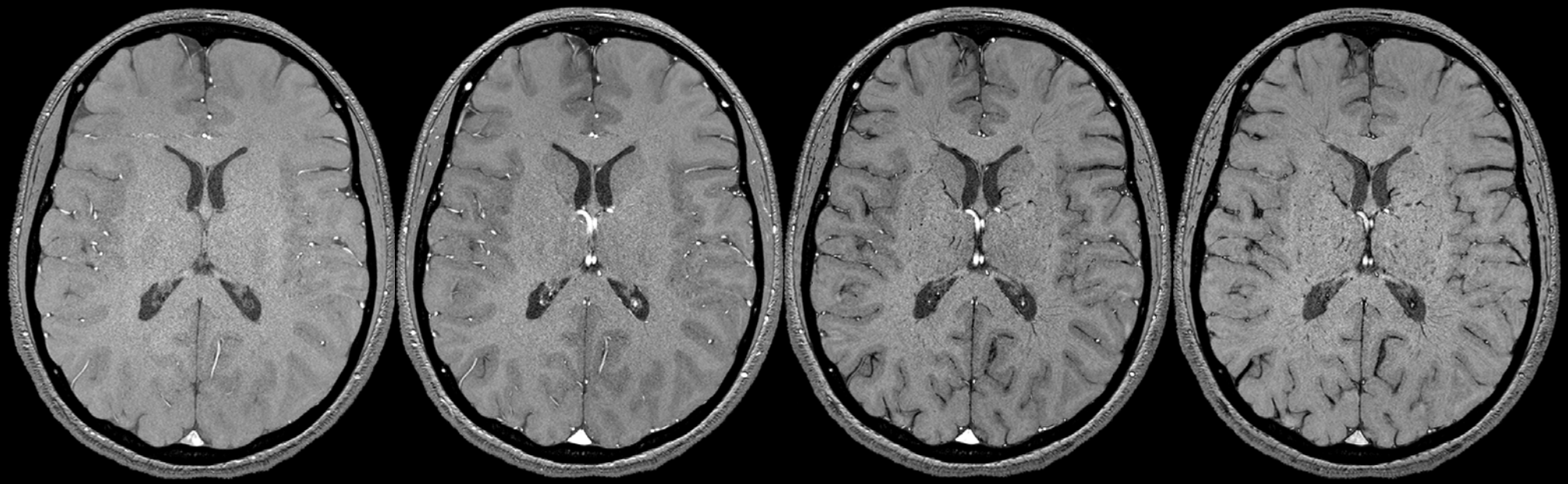

Pre-contrast (Fe_0) **Fe_1** **Fe_2** **Fe_3**

T_1-shortening due to Ferumoxytol: Venous Enhancement

Magnitude TE_1

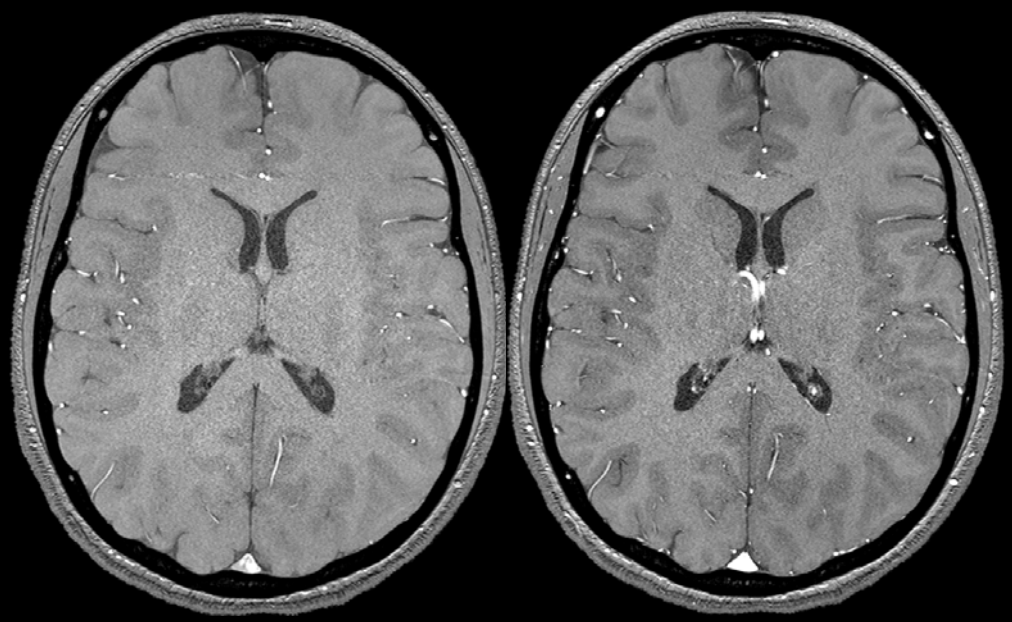

Pre-contrast (Fe_0) Fe_1

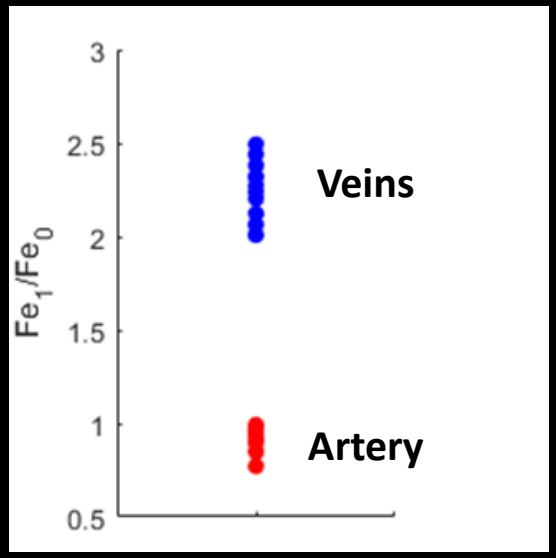

T_1-shortening due to Ferumoxytol: Venous Enhancement

Magnitude TE_1

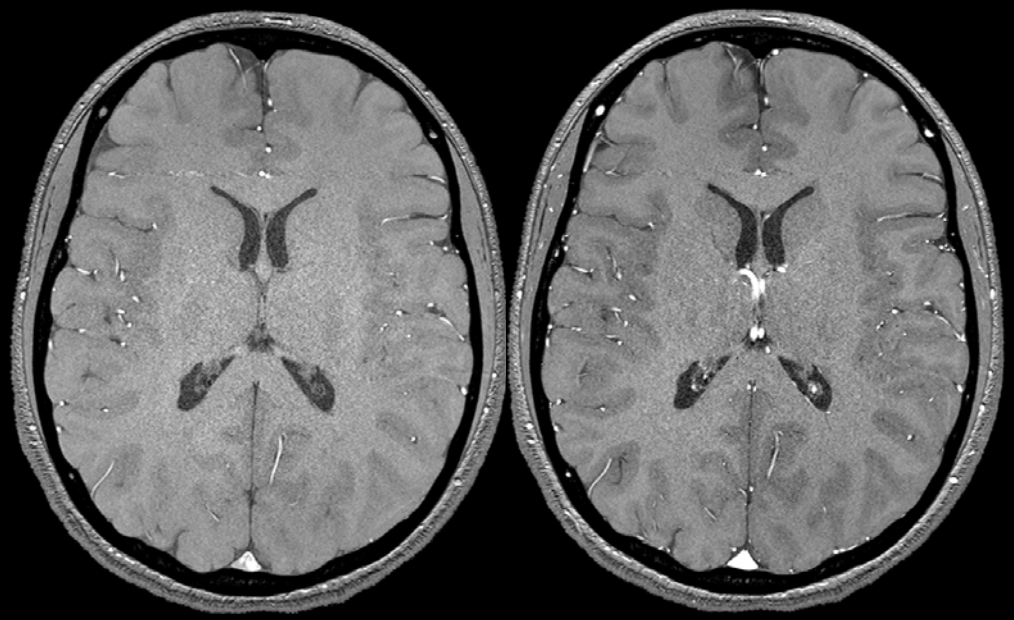

Pre-contrast (Fe_0)

Fe_1

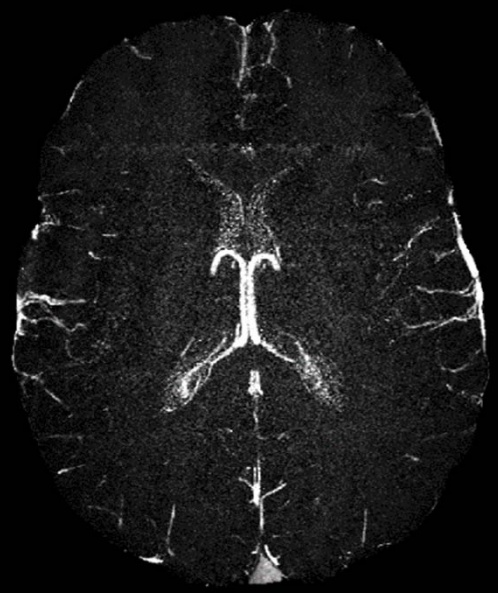

Imaging the Veins with MICRO

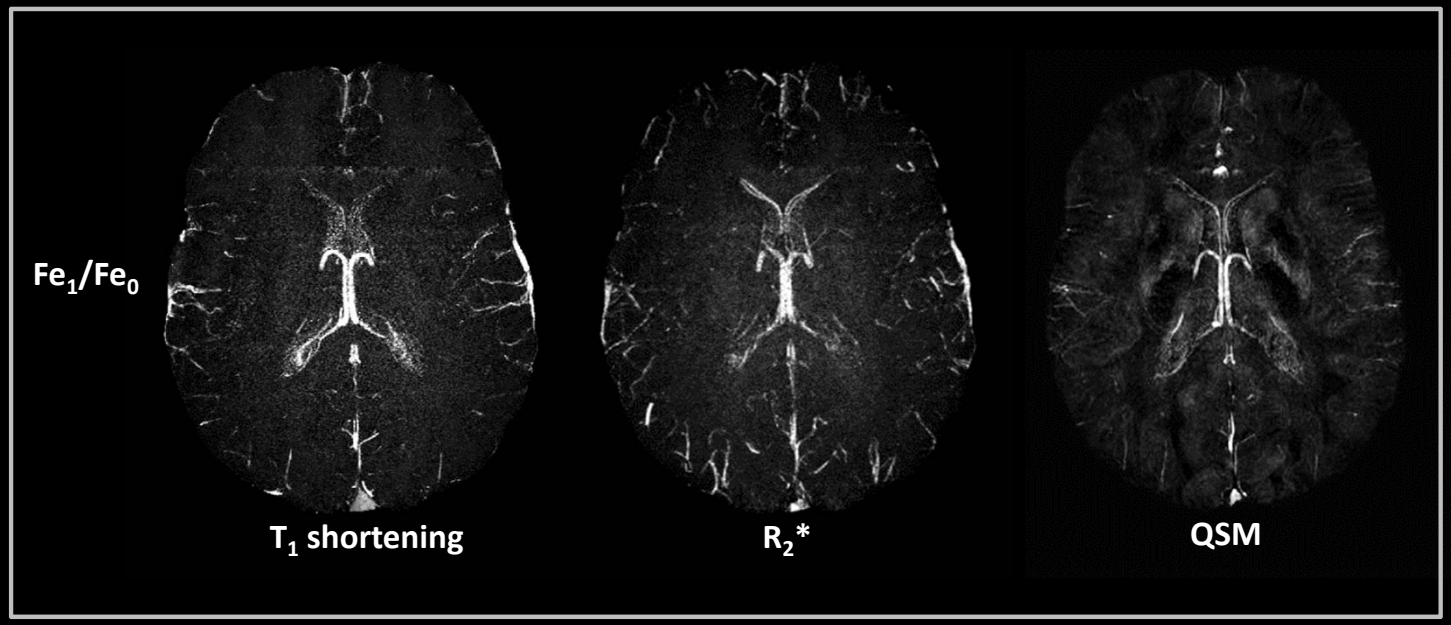

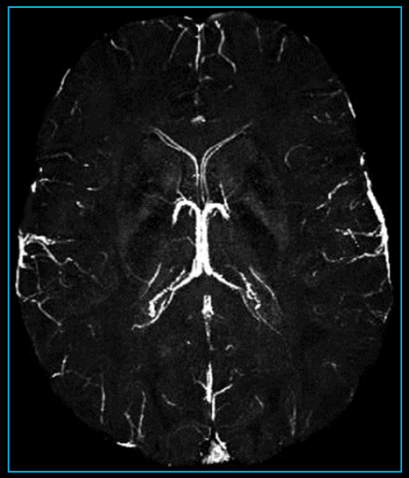

Mean venous map

Using the first hand MRA and these final mean venous maps, we can begin to identify the major arteries and veins in MICRO.

Mapping Cerebral Vessels

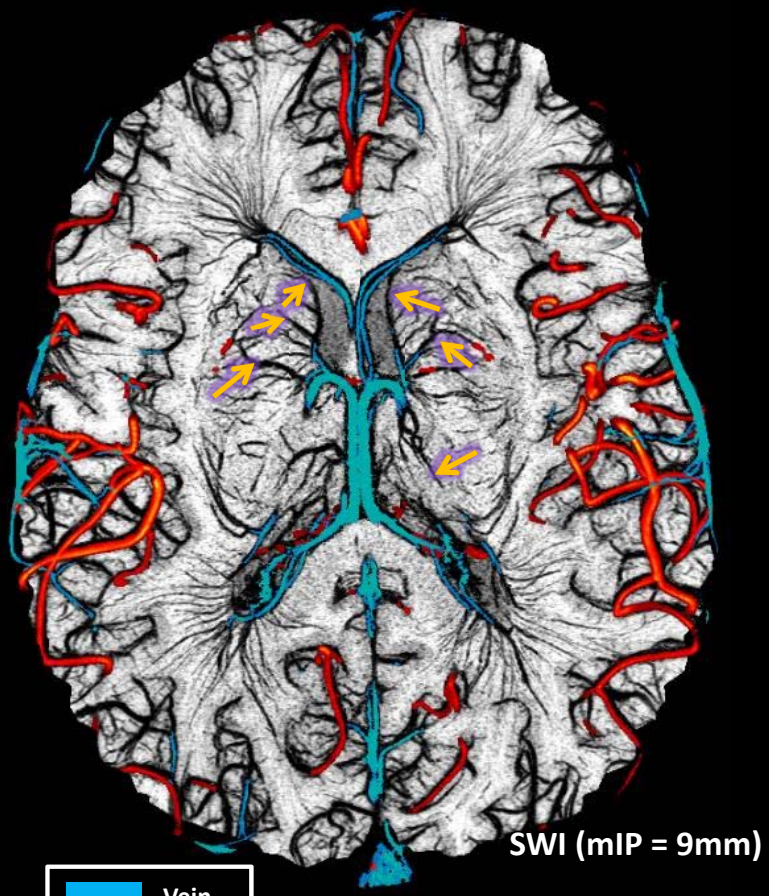

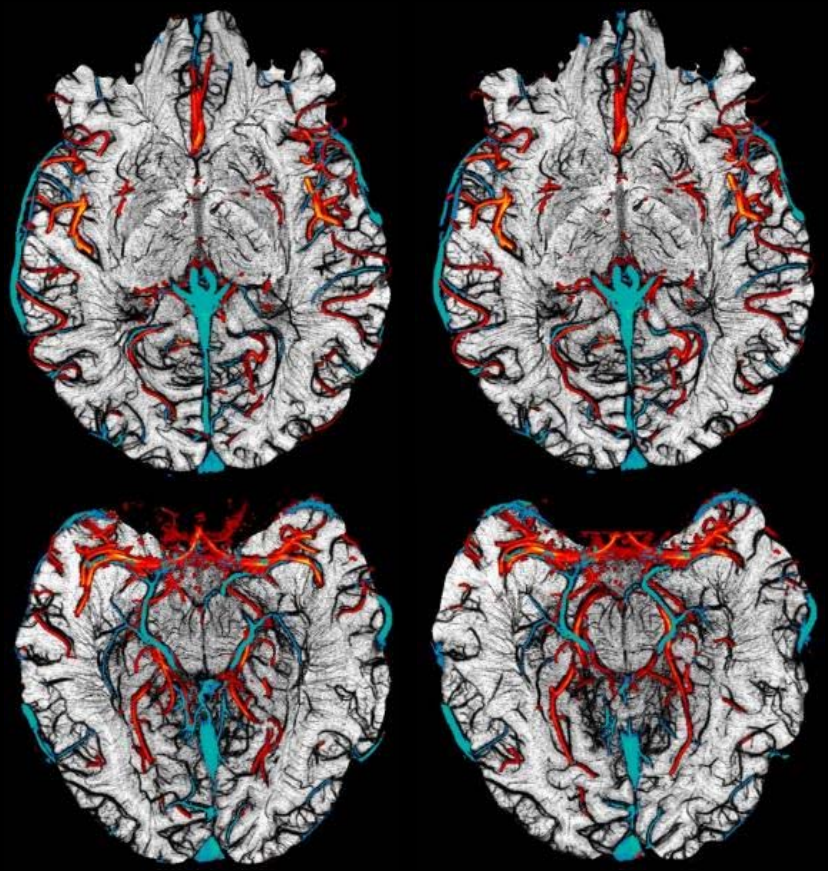

Vein

Artery

Venous tributaries

3T Images

Comparison of MICRO and Cadaver brain data: Midbrain

MICRO SWI

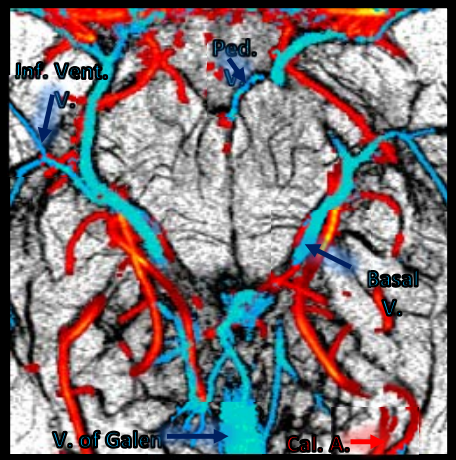

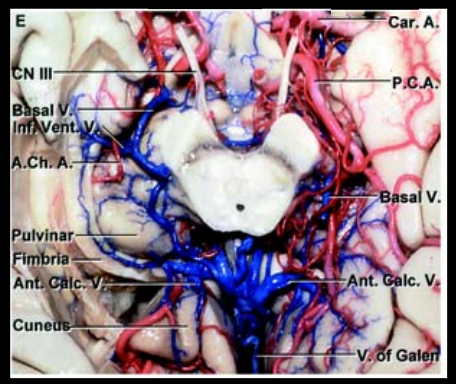

Cadaver data

MICRO SWI

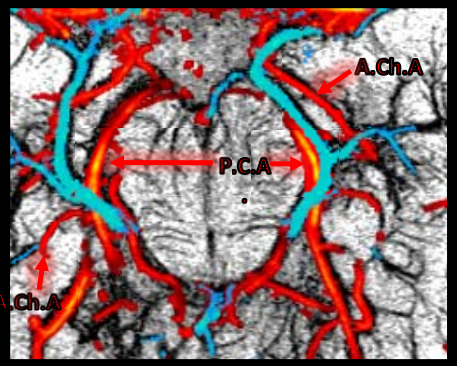

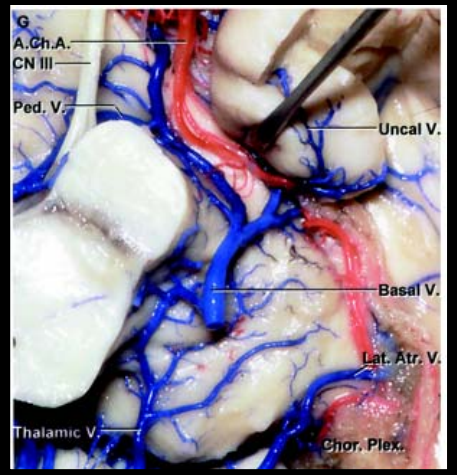

Cadaver data

Albert L. Rhoton, Jr., M.D., The Cerebral Veins, *Neurosurgery*, Volume 51, Issue suppl_4, 1 October 2002, Pages S1–159–S1–205

Dynamic Combination of USPIO-SWI data

Post contrast SWI (mIP = 8mm)

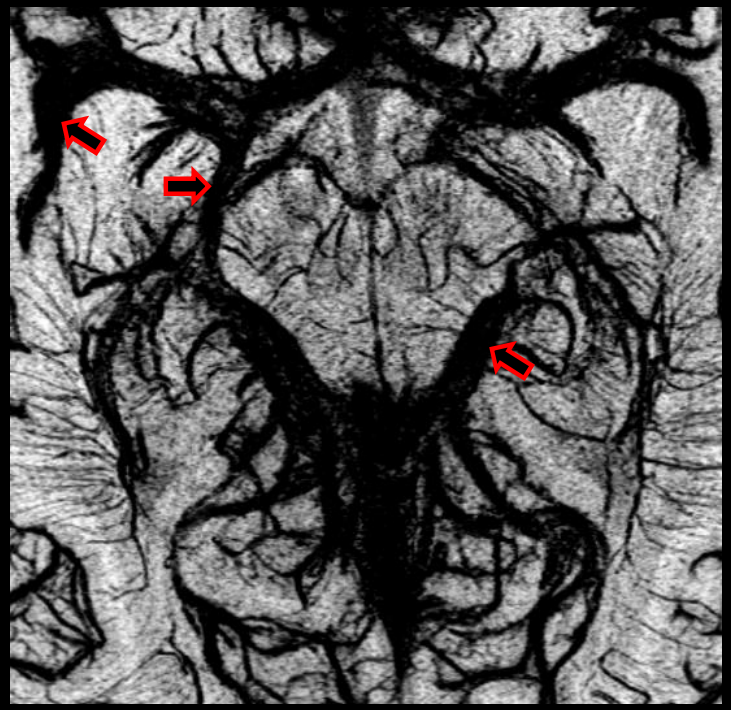

Buch S, Wang Y, Park MG, et al. **Subvoxel vascular imaging of the midbrain using USPIO-Enhanced MRI**. *Neuroimage*. 2020;220:117106.

Dynamic Combination of USPIO-SWI data

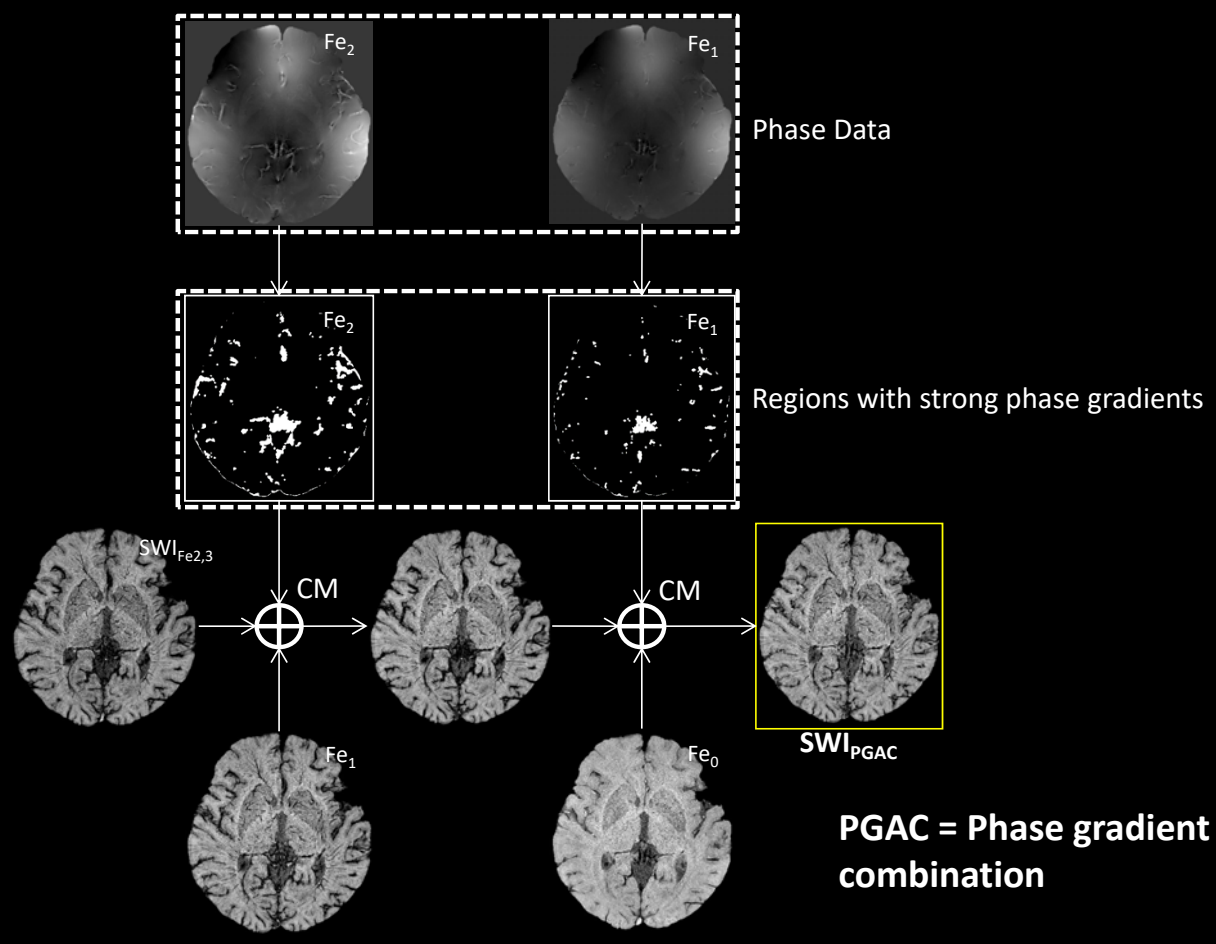

PGAC = Phase gradient based adaptive combination

Buch S, Wang Y, Park MG, et al. **Subvoxel vascular imaging of the midbrain using USPIO-Enhanced MRI**. *Neuroimage*. 2020;220:117106.

Dynamic Combination of USPIO-SWI data

To reduce the blooming artifact and better identify vessels

Post contrast SWI (mIP = 8mm) | **SWI_{PGAC} (mIP = 8mm)**

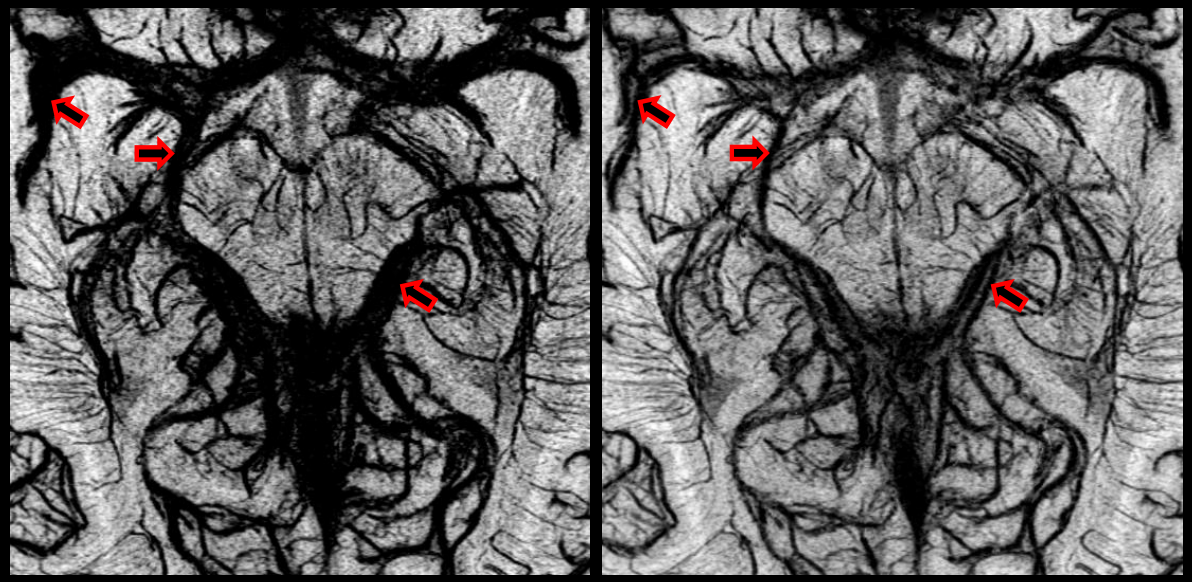

PGAC = Phase-gradient based adaptive combination

3T Images

Buch S, Wang Y, Park MG, et al. **Subvoxel vascular imaging of the midbrain using USPIO-Enhanced MRI**. *Neuroimage*. 2020;220:117106.

Comparison of MICRO and Cadaver brain dye injection

3T SWI (mIP=8mm)

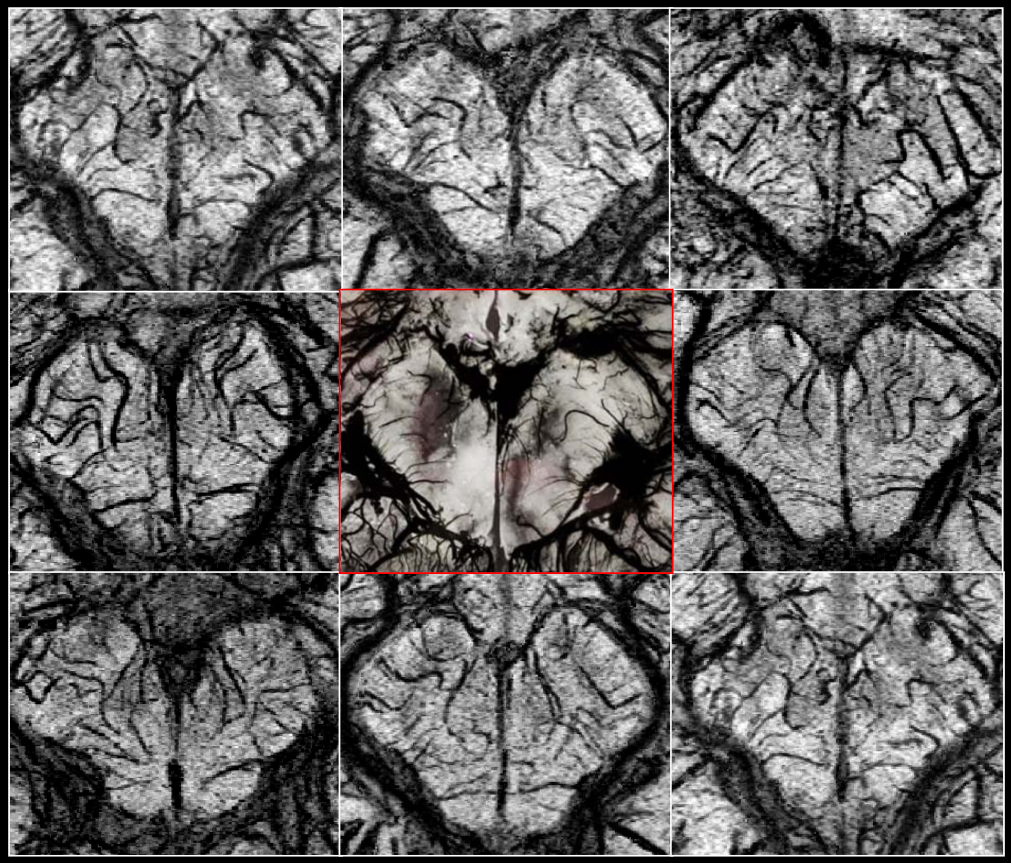

Center image:
***In vitro* angiogram**

Georges Salamon; J M Corbaz
Atlas de la vascularisation arterielle du cerveau chez l'homme

Buch S, et al. **Subvoxel vascular imaging of the midbrain using USPIO-Enhanced MRI.** *Neuroimage*. 2020;220:117106.

Mapping the Connectivity of the Midbrain Vessels

Major brainstem arteries:
AChA = anterior choriodal artery,
IMA = inferior medial mesencephalic,
MHA = medial hippocampal,
PCA = posterior cerebral,
PChA = posterior choroidal,
PComA = posterior communicating,
PHA = posterior hippocampal,
PmChA = posterior-medial choriodal,
SCA = superior cerebral artery.

Major brainstem veins:
BV = basal vein,
IVV = inferior ventricular vein,
IPV = interpeduncular vein,
VofG = vein of Galen.

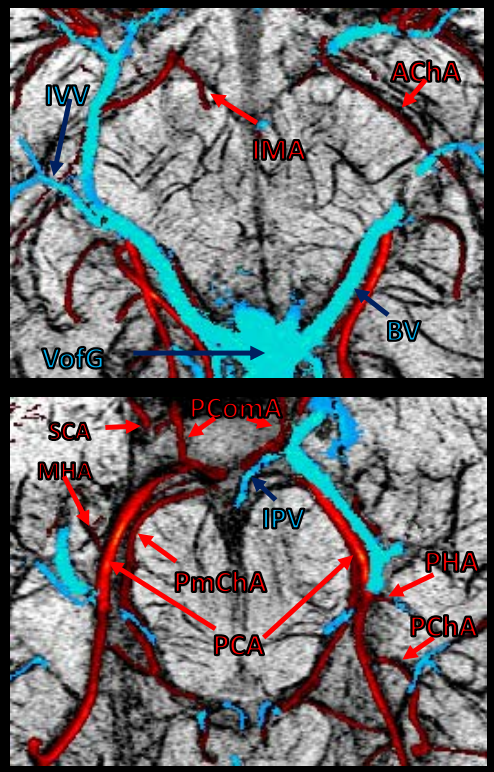

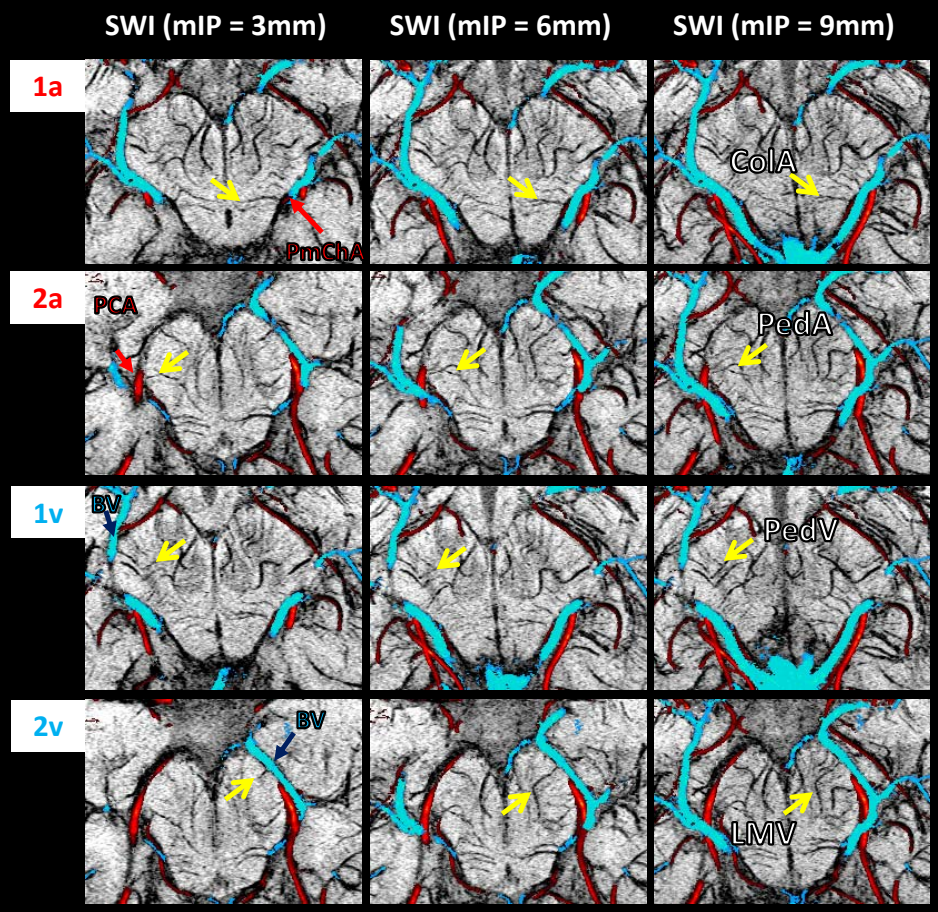

(1a) the collicular artery (ColA);
(2a) peduncular artery (PedA);
(1v) peduncular vein (PedV) and
(2v) branch of the lateral mesencephalic vein (LMV)

Vein Artery

Mapping the *Midbrain-Hippocampal* Vasculature using MICRO

3T Images

Post contrast SWI

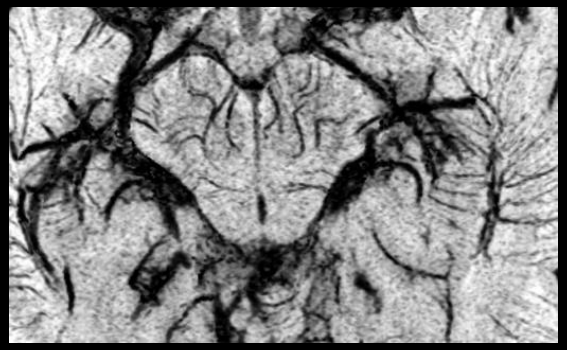

Pre constrast QSM

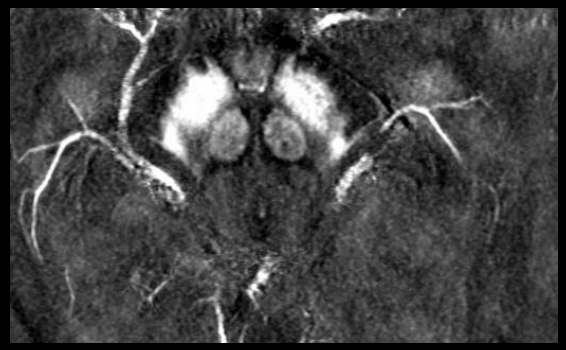

mIP/MIP = 8mm

Pre contrast QSM + Vessel overlay

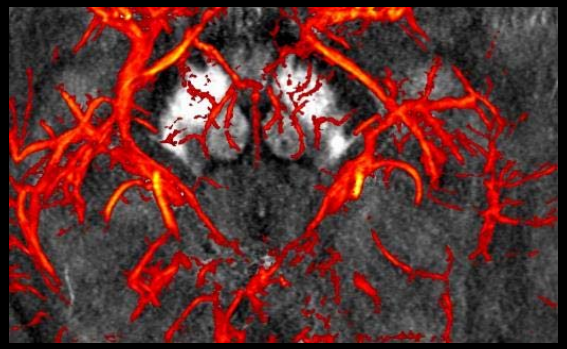

Post contrast vessel enhancement

Midbrain schematic

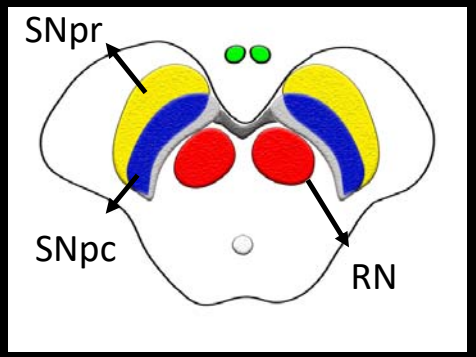

Mapping the Micro-vasculature

Utilizing The Frangi Vesselness Filter to Suppress Background Signal

Hessian Matrix

$$H(f) = \begin{bmatrix} \frac{\partial^2 f}{\partial x_1^2} & \frac{\partial^2 f}{\partial x_1 \partial x_2} & \cdots & \frac{\partial^2 f}{\partial x_1 \partial x_n} \\ \frac{\partial^2 f}{\partial x_2 \partial x_1} & \frac{\partial^2 f}{\partial x_2^2} & \cdots & \frac{\partial^2 f}{\partial x_2 \partial x_n} \\ \vdots & \vdots & \ddots & \vdots \\ \frac{\partial^2 f}{\partial x_n \partial x_1} & \frac{\partial^2 f}{\partial x_n \partial x_2} & \cdots & \frac{\partial^2 f}{\partial x_n^2} \end{bmatrix}$$

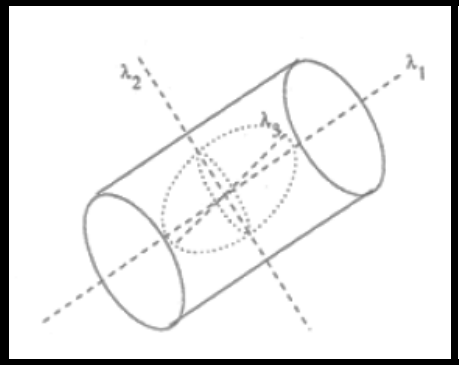

2D		3D			orientation pattern
λ_1	λ_2	λ_1	λ_2	λ_3	
N	N	N	N	N	noisy, no preferred direction
		L	L	H-	plate-like structure (bright)
		L	L	H+	plate-like structure (dark)
L	H-	L	H-	H-	tubular structure (bright)
L	H+	L	H+	H+	tubular structure (dark)
H-	H-	H-	H-	H-	blob-like structure (bright)
H+	H+	H+	H+	H+	blob-like structure (dark)

$$R_B = \frac{|\lambda_1|}{\sqrt{|\lambda_2 \lambda_3|}} \quad R_A = \frac{|\lambda_2|}{|\lambda_3|} \quad S = \sqrt{\lambda_1^2 + \lambda_2^2 + \lambda_3^2}.$$

$$V(\sigma) = \begin{cases} 0 & \text{if } \lambda_2 < 0 \text{ or } \lambda_3 < 0, \\ \left(1 - \exp\left(-\frac{R_A^2}{2\alpha^2}\right)\right) \exp\left(-\frac{R_B^2}{2\beta^2}\right)\left(1 - \exp\left(-\frac{S^2}{2c^2}\right)\right). \end{cases}$$

Frangi A.F., Niessen W.J., Vincken K.L., Viergever M.A. (1998) Multiscale vessel enhancement filtering. In: Wells W.M., Colchester A., Delp S. (eds) Medical Image Computing and Computer-Assisted Intervention — MICCAI'98. Lecture Notes in Computer Science, vol 1496. Springer, Berlin, Heidelberg

Utilizing The Frangi Vesselness Filter to Suppress Background Signal

MIP = 8mm

SWI

Vessel map

Mean (Vessel map and vesselness)

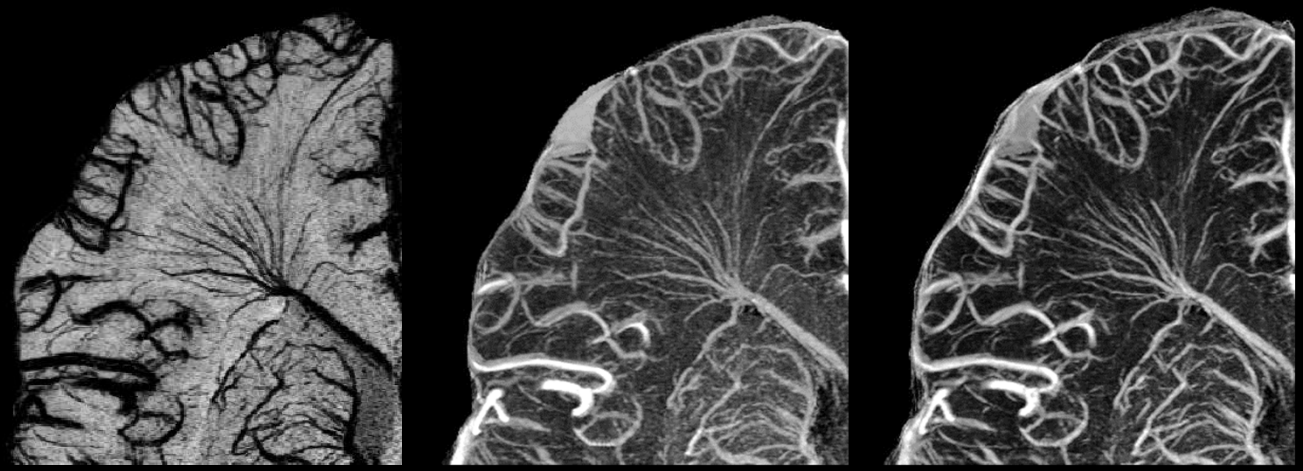

3T Images

Frangi A.F., Niessen W.J., Vincken K.L., Viergever M.A. (1998) Multiscale vessel enhancement filtering. In: Wells W.M., Colchester A., Delp S. (eds) Medical Image Computing and Computer-Assisted Intervention — MICCAI'98. Lecture Notes in Computer Science, vol 1496. Springer, Berlin, Heidelberg

Extracting the Cerebral Vasculature

Medullary veins

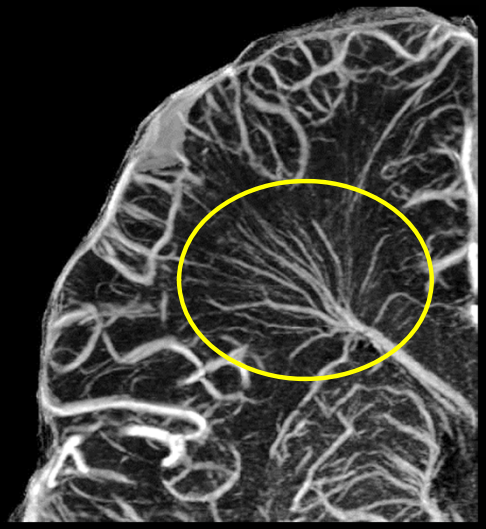

Extracted Medullary veins

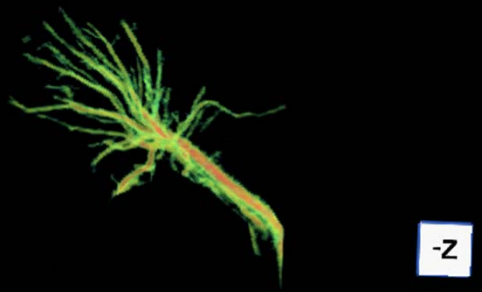

Applications of MICRO Imaging: Hippocampal Microvasculature

3T Images

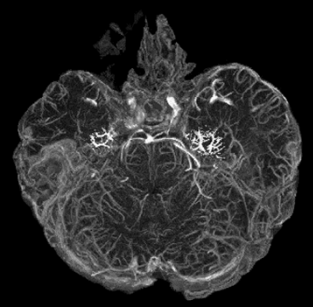

Cerebral vessels

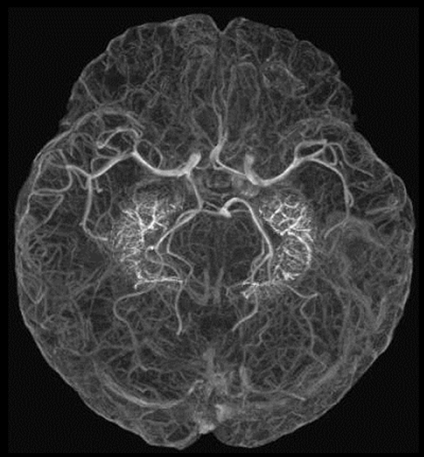

Isolated hippocampal vessels

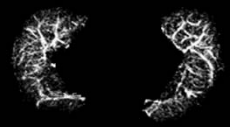

For the first time, we can isolate and visualize the vessels of the hippocampus *in vivo*

Hippocampus Vessel Extraction

3T Images

mIP/MIP = 3cm

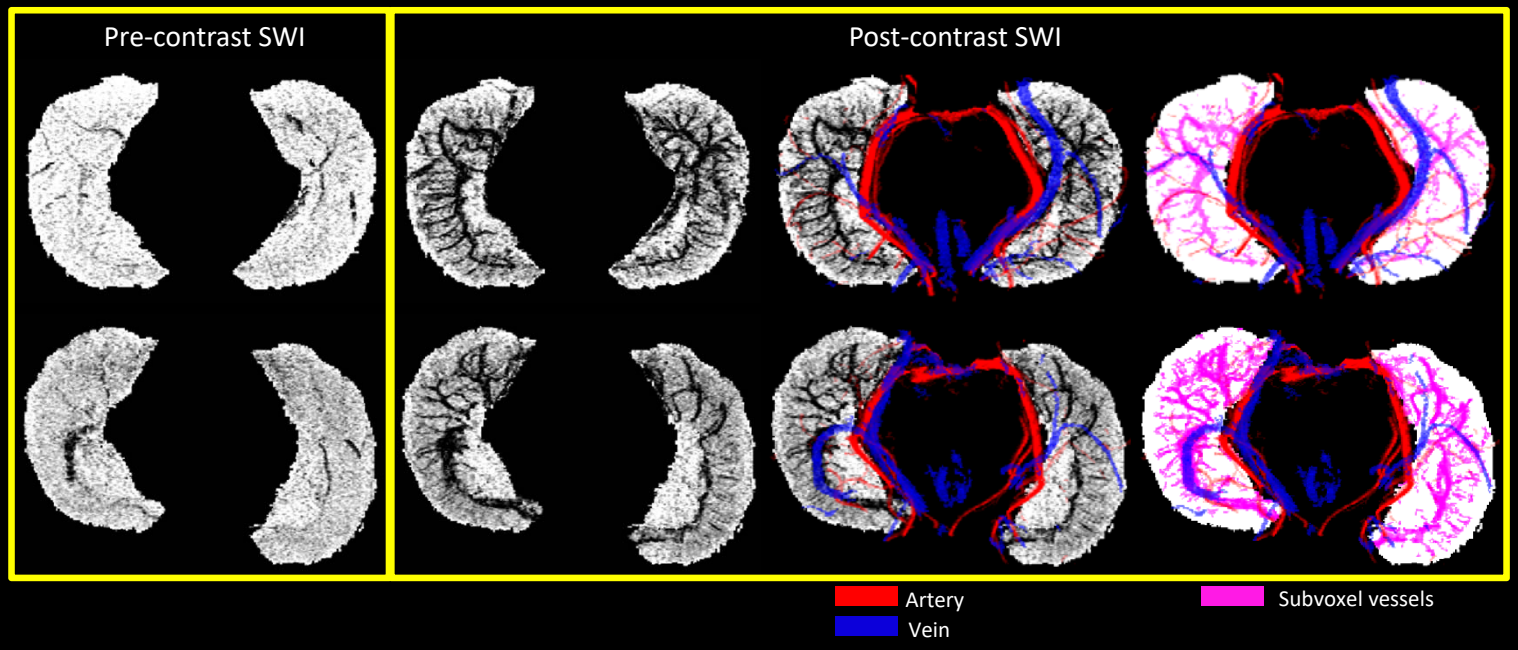

Hippocampal Macro- and Micro-vasculature

3T Images

Illustration of Hippocampal vascularization

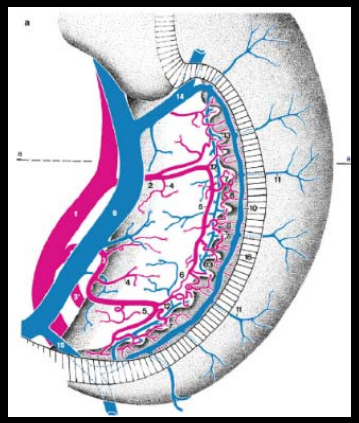

Vascular ink injection (cadaver)

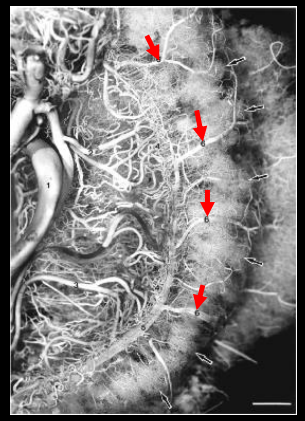

MICRO SWI (Ferumoxytol)

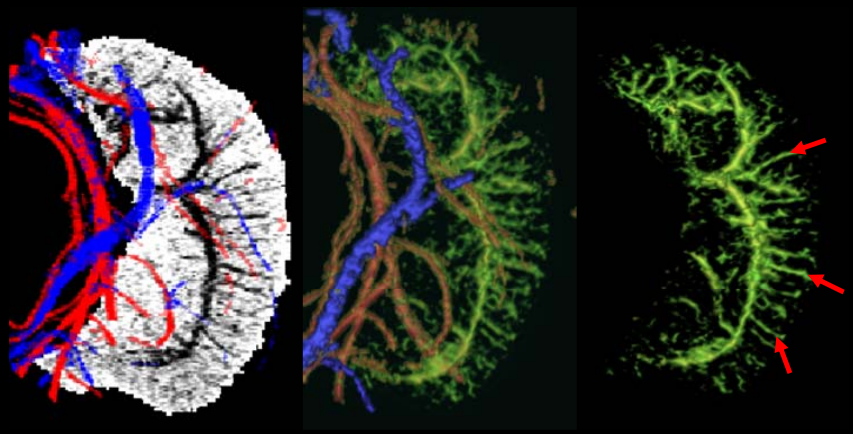

Duvernoy et al., The Human Hippocampus: Functional Anatomy, Vascularization and Serial Sections with MRI. 2013, 4th edition, Springer-Verlag Berlin Heidelberg, pg. 74 and 99.

→ Subependymal intra-hippocampal veins

Segmenting the Hippocampal Subfields

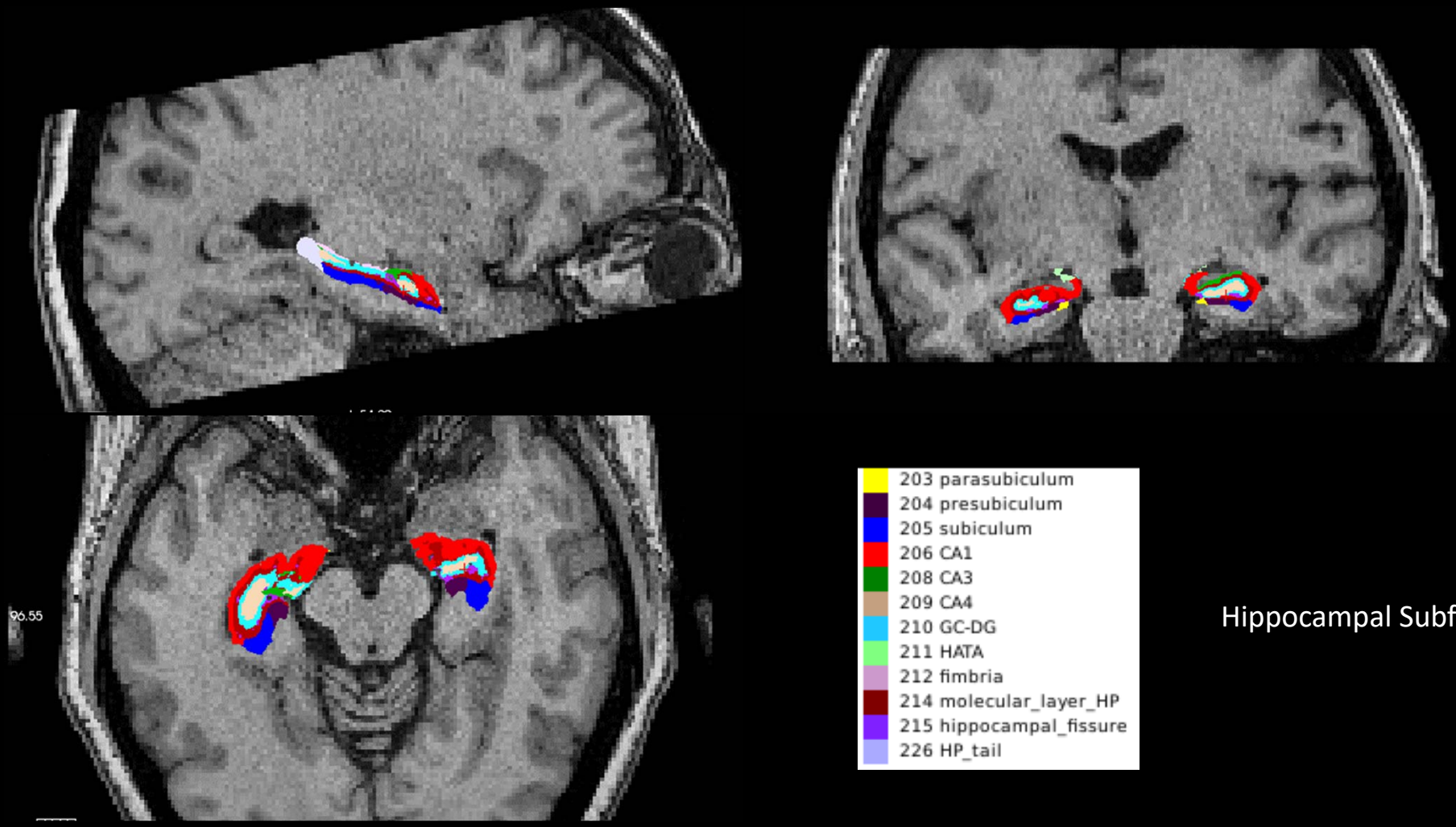

Hippocampal Subfields

Vessel Density of Different Hippocampal Sub-fields

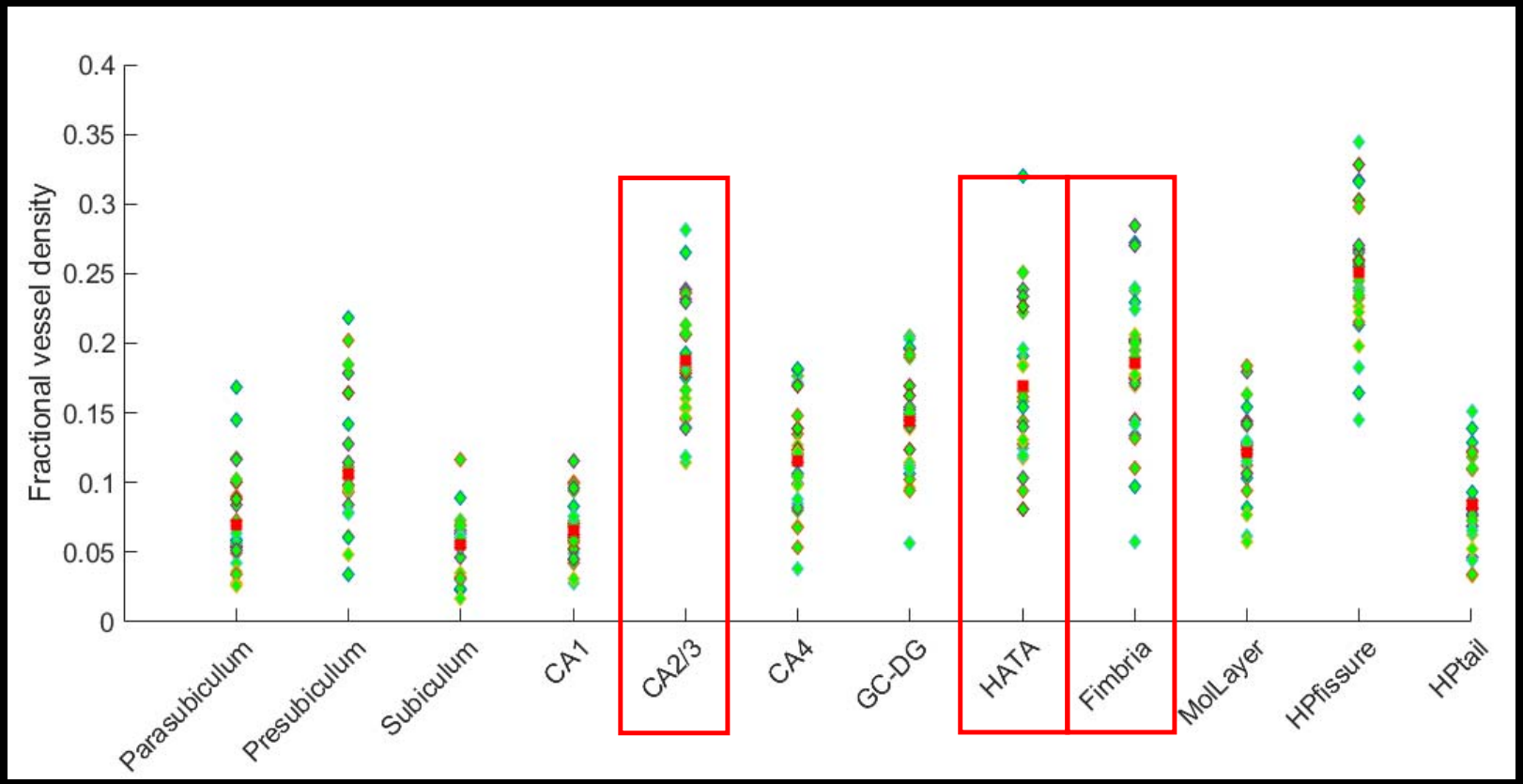

GC-DG = Granule cell layer of the dentate gyrus, HATA = Hippocampal-amygdaloid transition region, MolLayer = Molecular layer of HP

Hippocampal Subfields with Cortical Surface

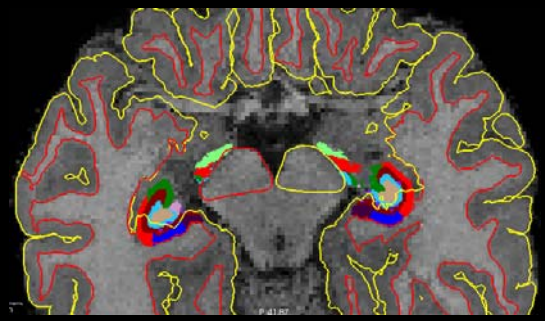

Axial view

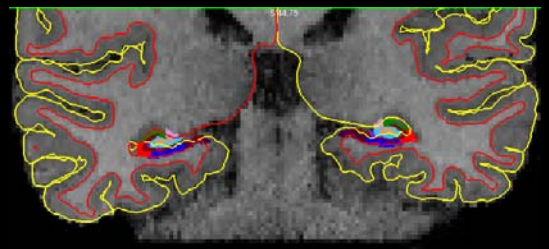

Coronal view

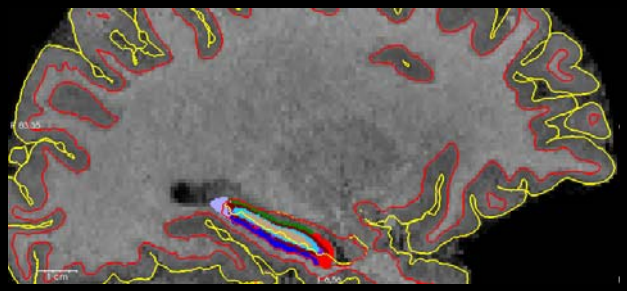

Sagittal view

Inter-subject Registration

Subject A

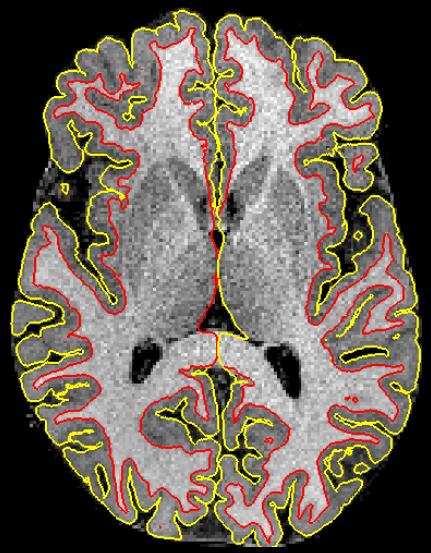

Subject B

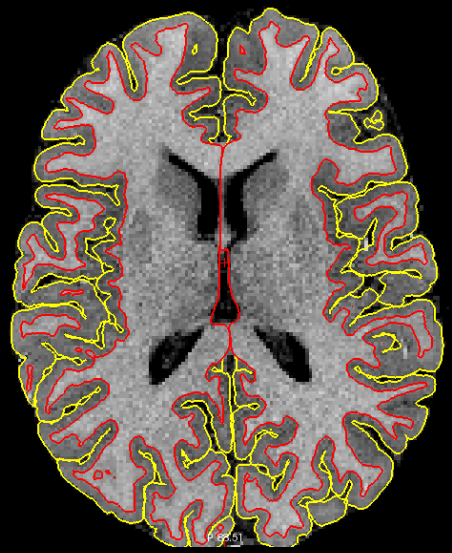

Subject A'

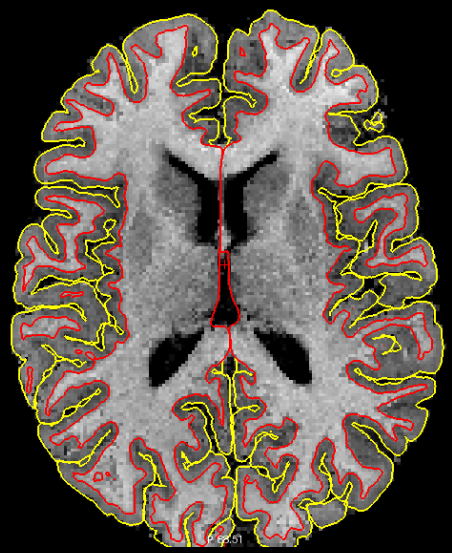

CVS registration: G.M. Postelnicu*, L. Zöllei*, B. Fischl: "Combined Volumetric and Surface Registration", IEEE Transactions on Medical Imaging (TMI), Vol 28 (4), April 2009, p. 508-522.
L. Zöllei, A. Stevens, K. Huber, S. Kakunoori, B. Fischl: "Improved Tractography Alignment Using Combined Volumetric and Surface Registration", NeuroImage 51 (2010), 206-213

Inter-subject Registration

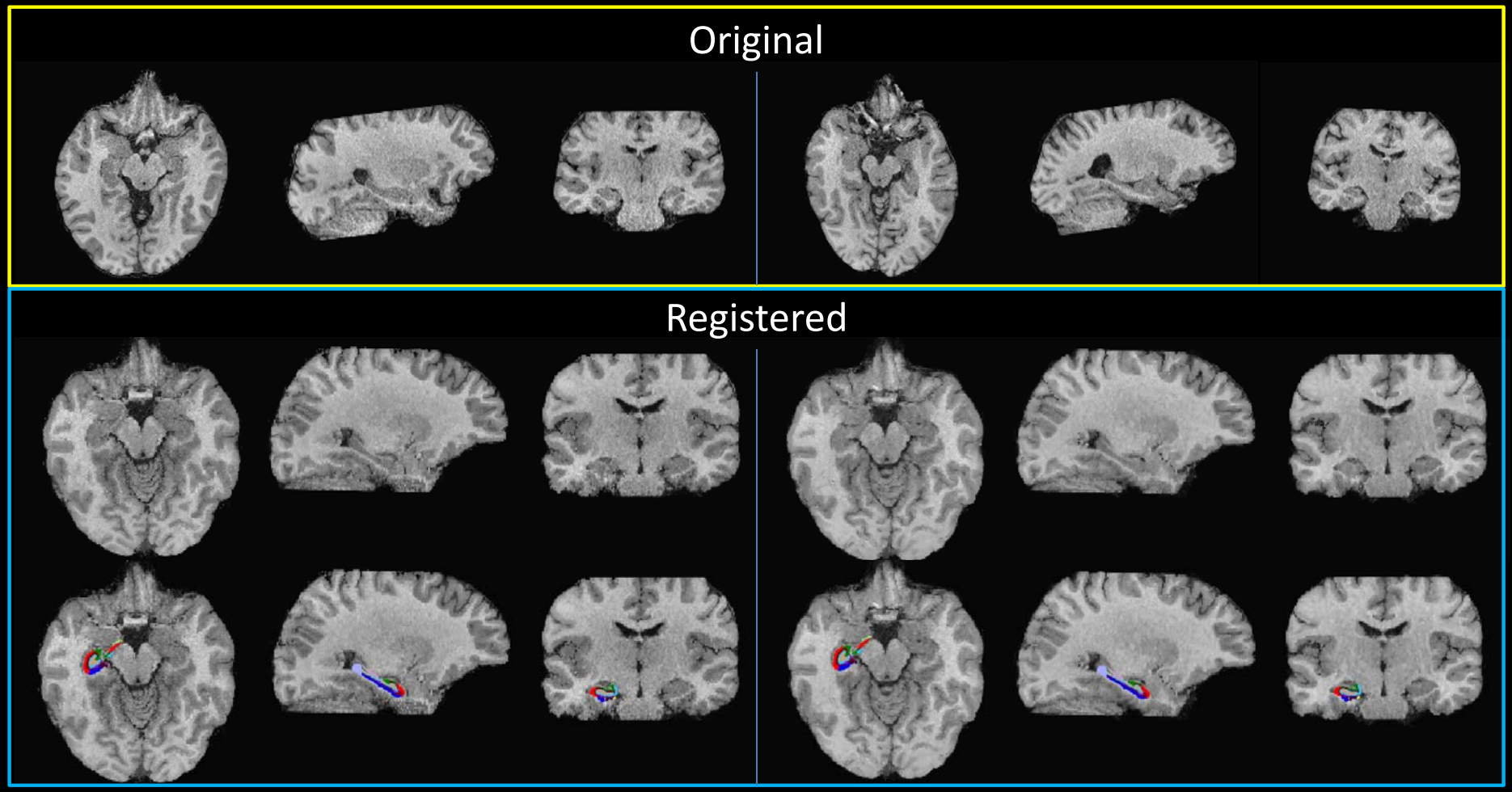

Template of the Cerebral Vasculature

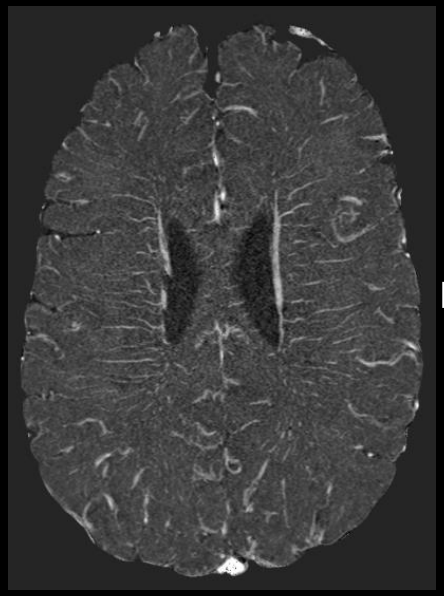

Vessel map

Co-registration

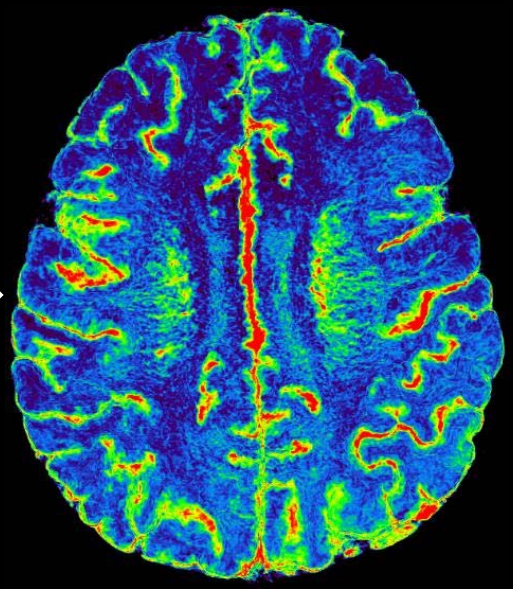

Co-registered **Mean Vessel map** (n=20)

CVS registration: G.M. Postelnicu, L. Zöllei, B. Fischl, IEEE Transactions on Medical Imaging (TMI), Vol 28 (4), April 2009, p. 508-522.
L. Zöllei, A. Stevens, K. Huber, S. Kakunoori, B. Fischl, NeuroImage 51 (2010), 206-213

Midbrain-Hippocampal Vasculature

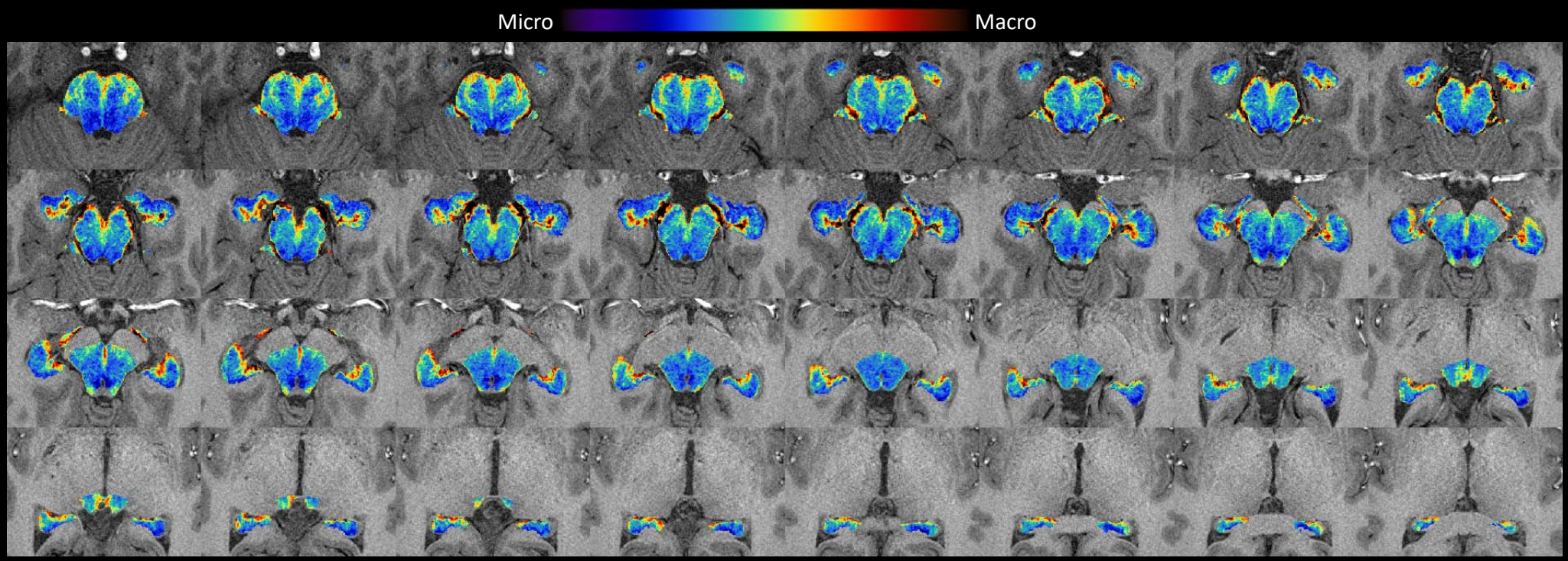

CVS registration: G.M. Postelnicu, L. Zöllei, B. Fischl, IEEE Transactions on Medical Imaging (TMI), Vol 28 (4), April 2009, p. 508-522.
L. Zöllei, A. Stevens, K. Huber, S. Kakunoori, B. Fischl, NeuroImage 51 (2010), 206-213

Applications of MICRO Imaging: Multiple Sclerosis

- Multiple Sclerosis (MS) is an inflammatory demyelinating disease
- Etiology of MS is understood to be autoimmune. However, a history exists with growing evidence for disrupted vasculature and flow within the disease pathology
- Multiple pathophysiological events may occur in a vicious circle including:

endothelial damage	venous collagenosis	fibrin deposition
loss of vessel compliance	venous hypertension	perfusion reduction
medullary vein dilation	local vascular remodeling	ischemia

- MICRO has potential to monitor the vasculature present in MS lesions and catalogue their characteristics, which may provide new insight into the pathophysiology of MS

Venous angioarchitecture in the cerebrum

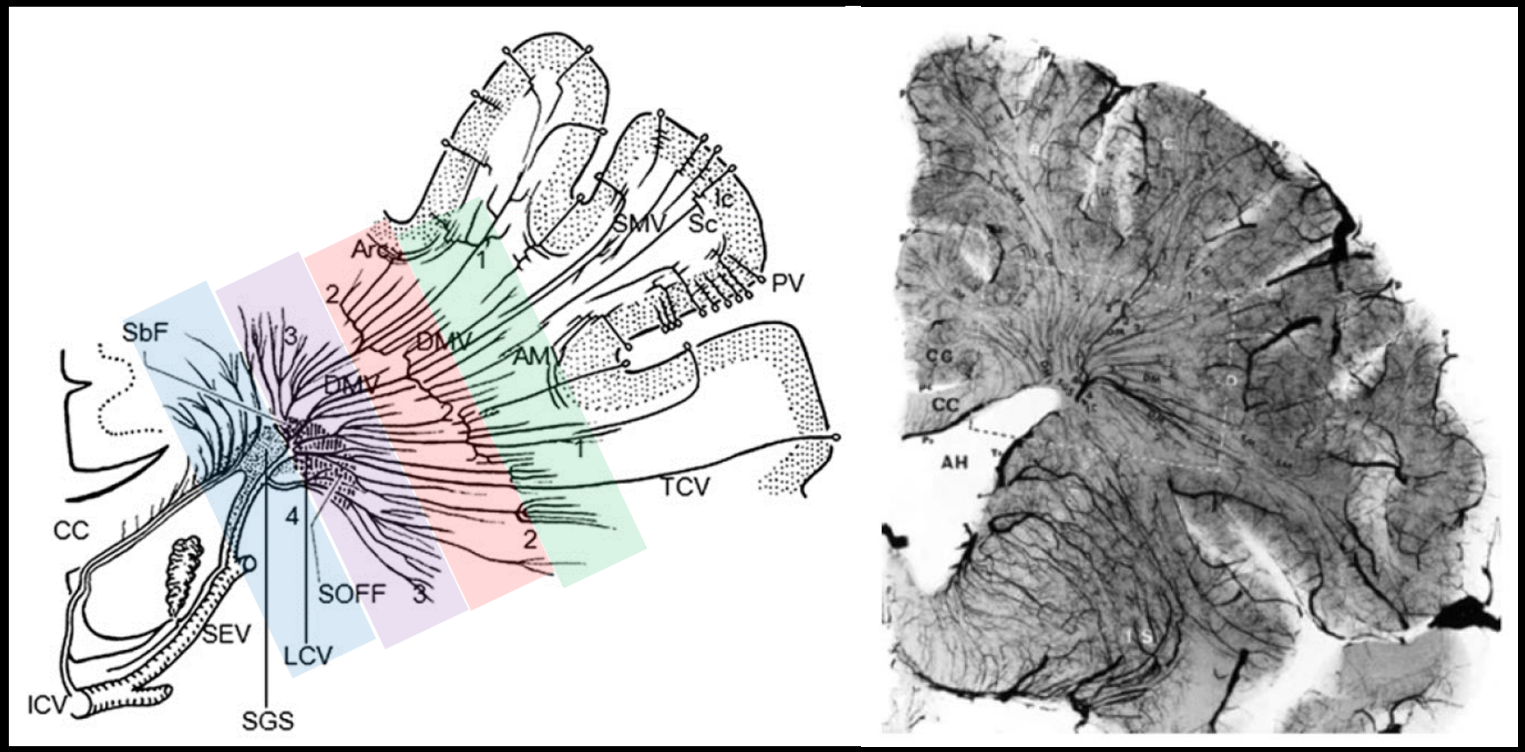

1 = first (or outer) zone of convergence
2 = second (or candelabra) zone of convergence
3 = third (or palmate) zone of convergence
4 = fourth (or subependymal) zone of convergence

Taoka, T. (2017).
Radiographics, 37, 281.

Generating SWI-FLAIR data

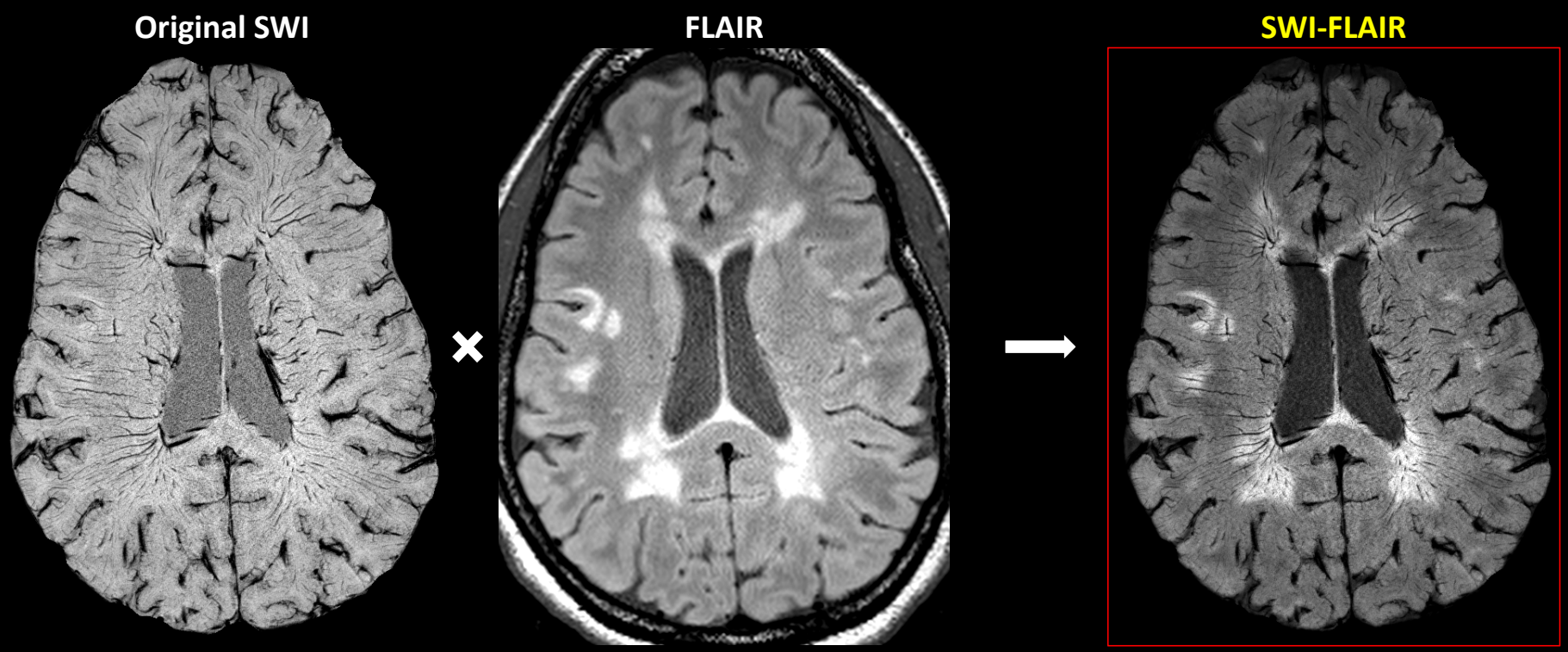

Classifying MS Vascular Anomalies

1. Small ovoid lesions
2. Vessel engorgement (matured collagenosis)
3. Perpendicular vessel development (corona radiata)
4. Venous angiomas

Identifying Vascular Anomalies using USPIO data

Small ovoid WMHs

WMH size *< 3 mm in-plane*
and 3 mm through plane



Location of the lesion surrounding a vessel

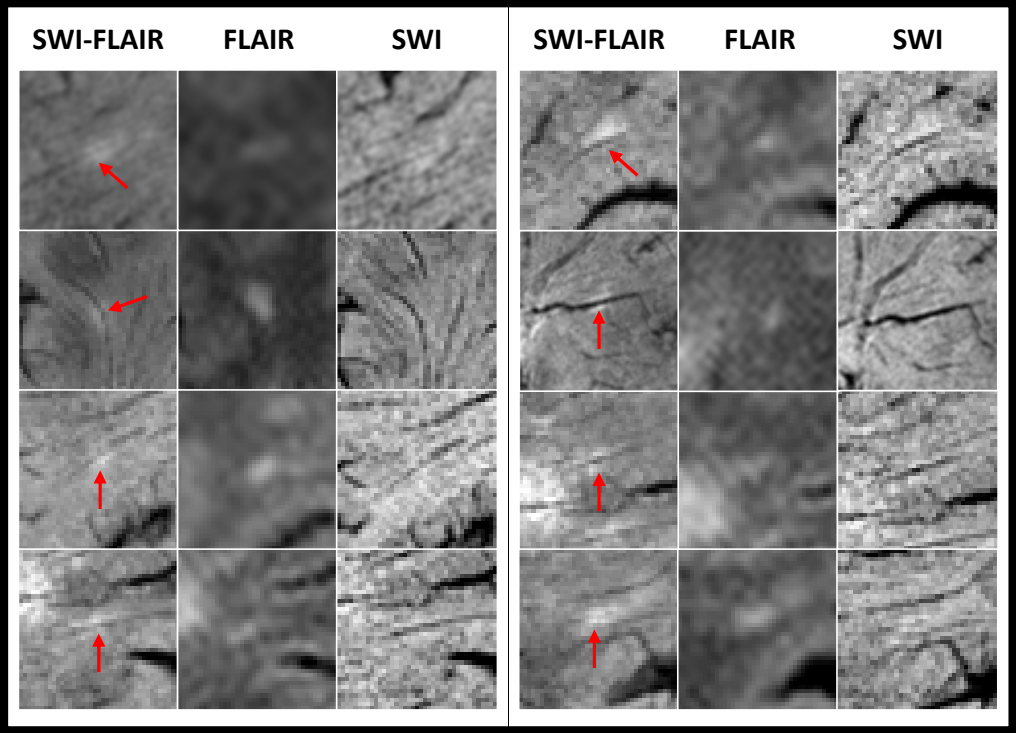

Identifying Vascular Anomalies using USPIO data

Dilated vessels show increased intra-lesional diameter with respect to the peri-lesional diameter.

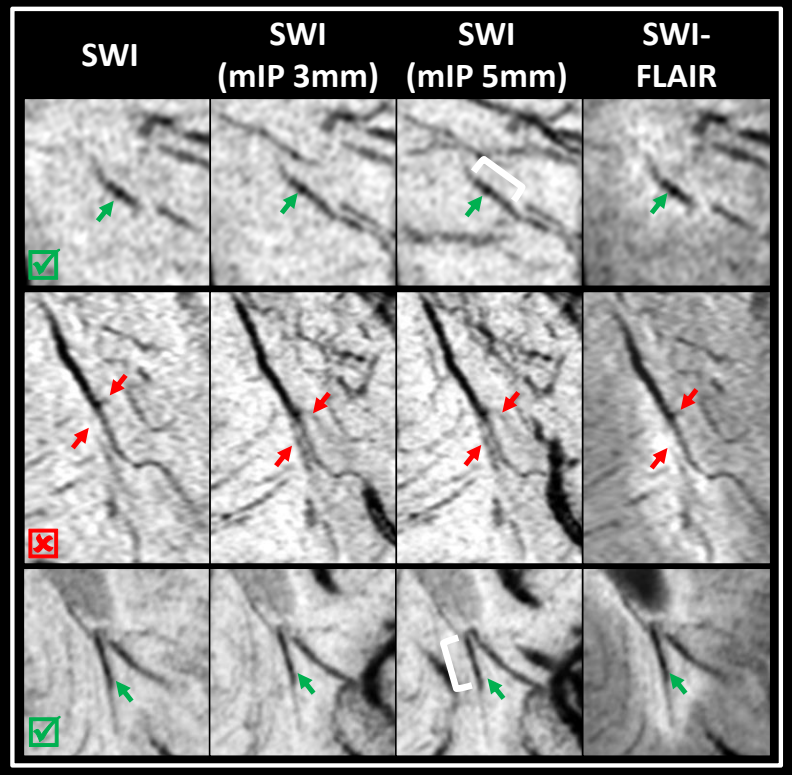

☑ Abnormally dilated vessel

☒ Natural dilation due to confluence

Identifying Vascular Anomalies using USPIO data

Perpendicular developing vessels

- A perpendicular vessel formation may suggest vascular remodeling (anastomosis), due to local obstructed flow caused by venous collagenosis.

- Usually observed at the boundary of the *corona radiata*

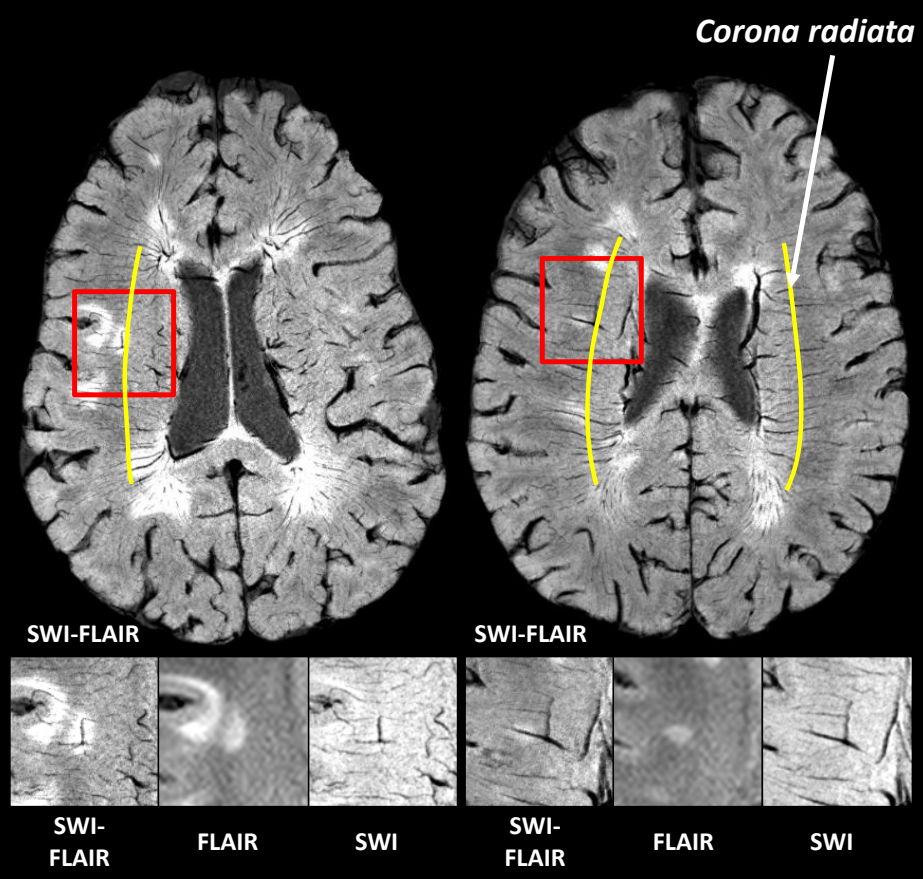

Identifying Vascular Anomalies using USPIO data

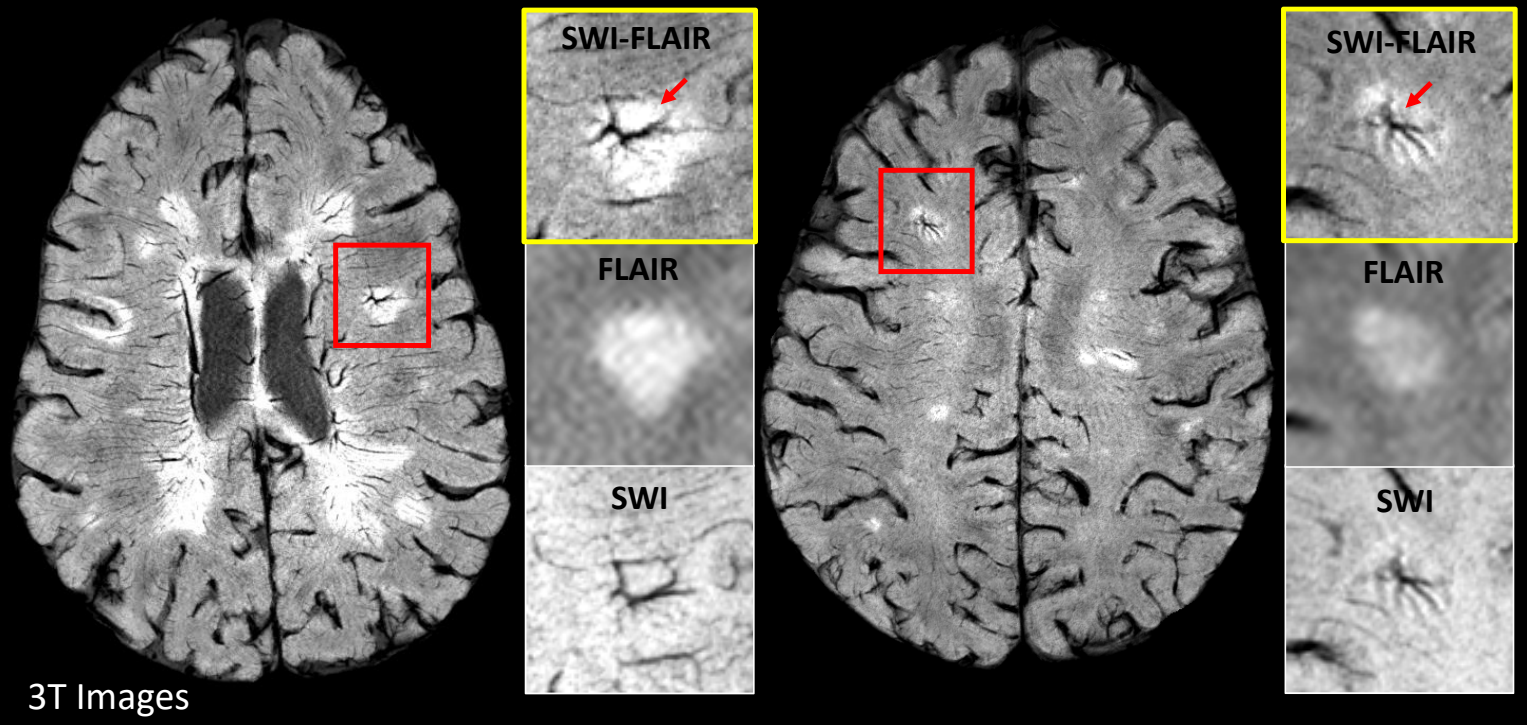

Atypical Venous Angiomas: Cerebro-vascular malformations that involve an irregular arrangement of vessels converging centripetally into a major vessel.

MICRO Imaging:

T_1 enhancement vs T_2* induced signal loss

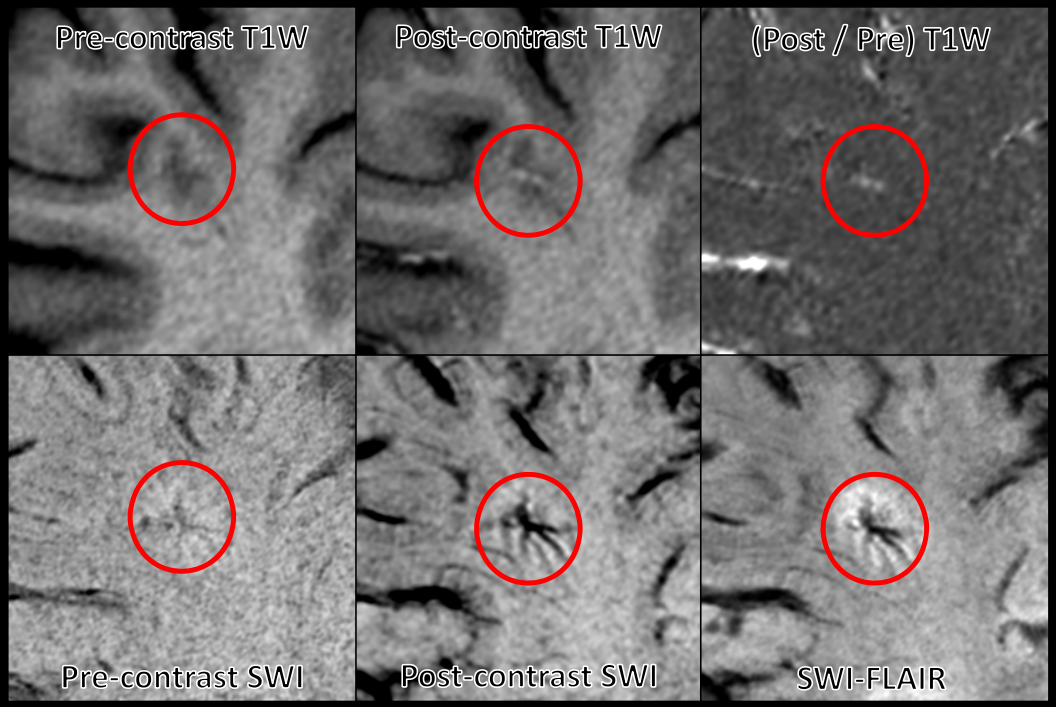

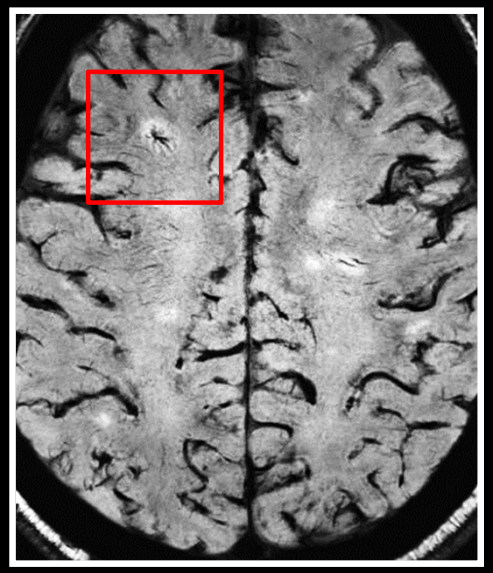

SWI-FLAIR

Identifying Vascular Signs in MS lesions

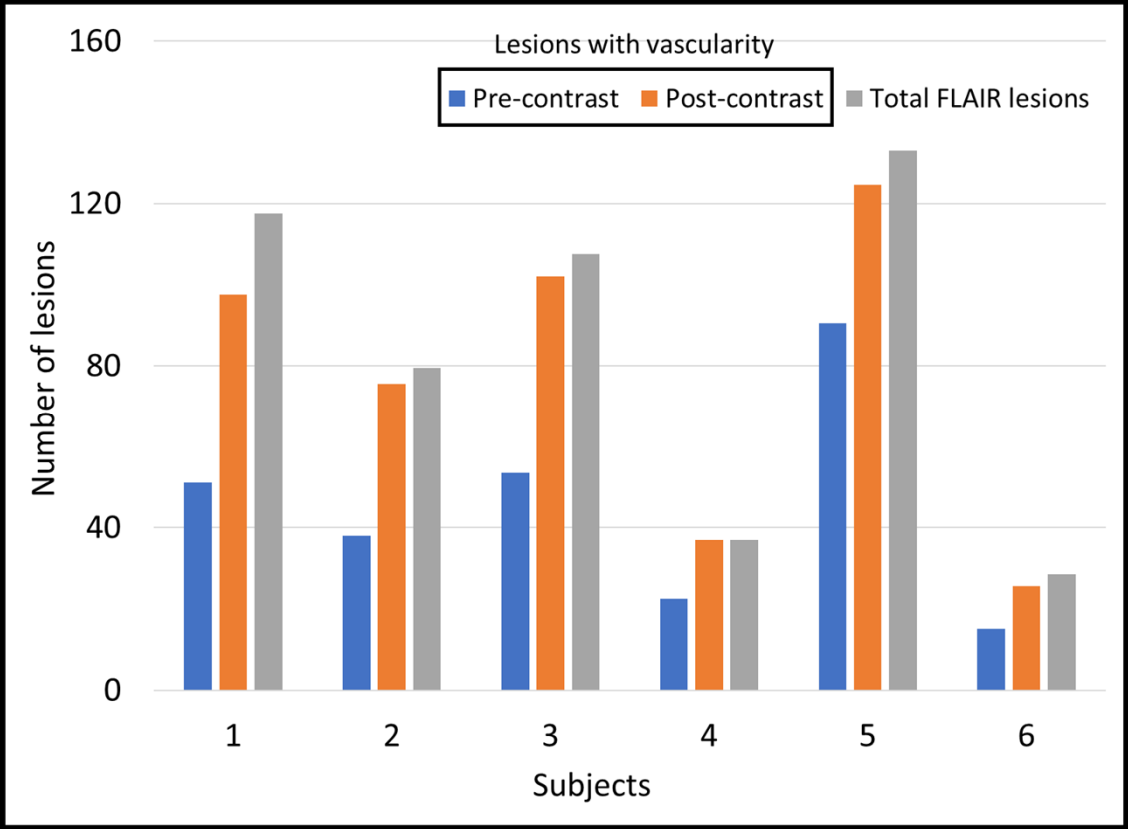

MICRO Imaging of the Medullary Veins and Multiple Sclerosis

Periventricular WM masks

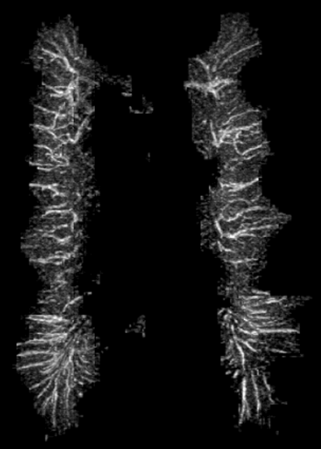

Periventricular WM vessels

Periventricular WM Extraction

Periventricular WM + Lesion map

Periventricular WM + Lesion map + Vessel map

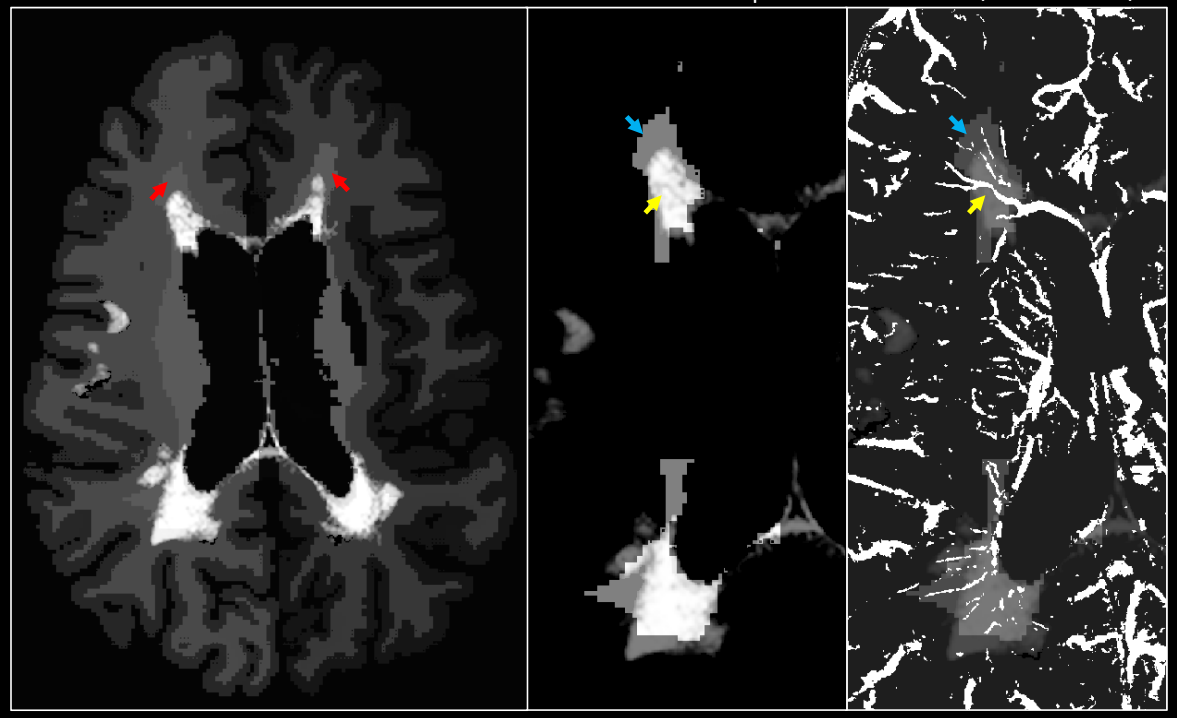

MICRO Imaging of the Medullary Veins and Multiple Sclerosis

Periventricular WM masks

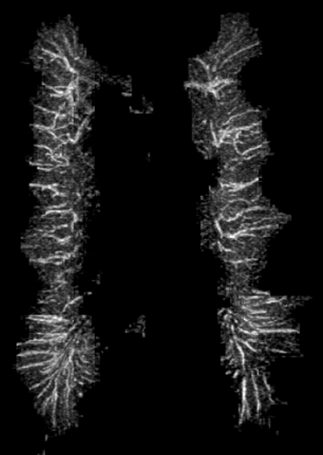

Periventricular WM vessels

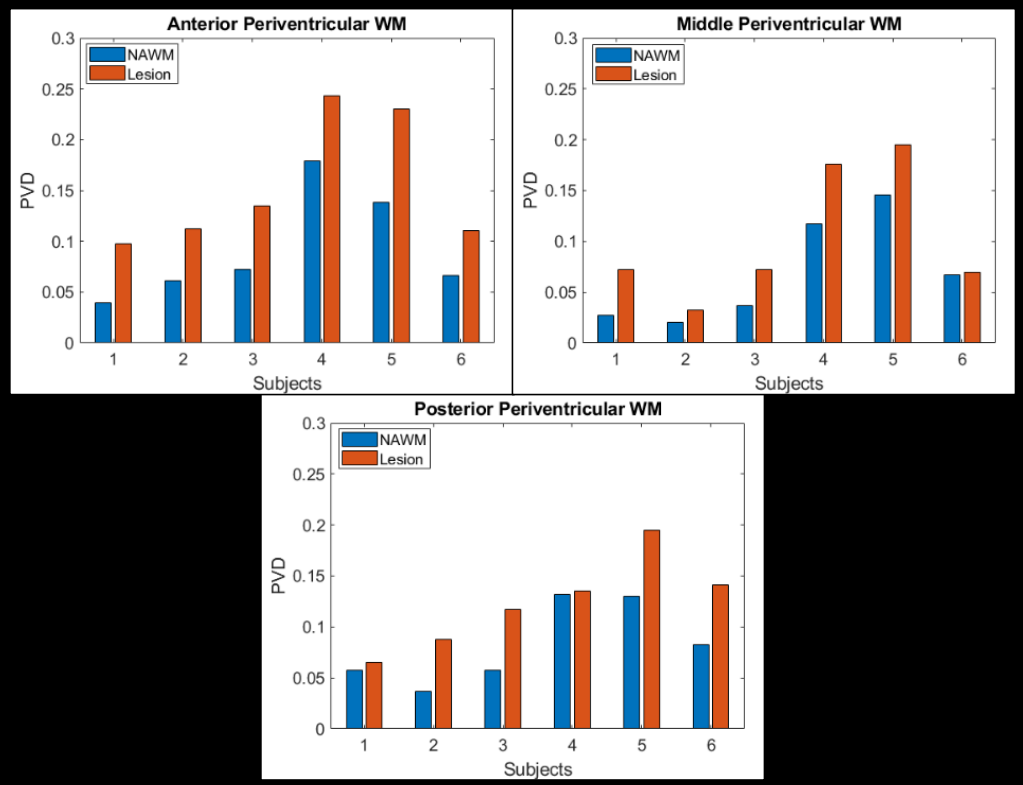

Lesional vessel density ***<u>is higher than</u>*** the NAWM vessel density in the periventricular region

MICRO Imaging of Tumors at 3T

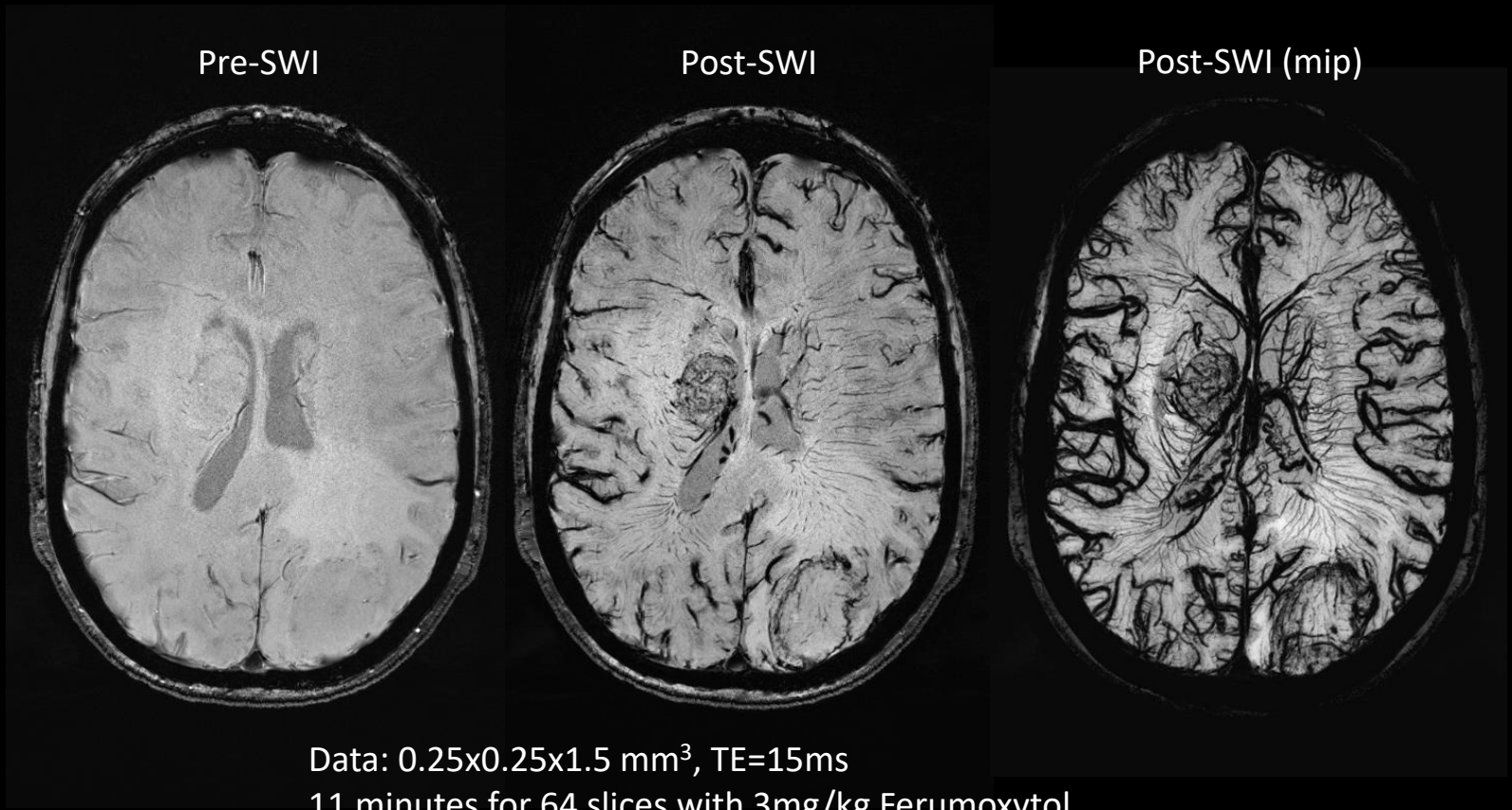

Data: 0.25x0.25x1.5 mm^3, TE=15ms
11 minutes for 64 slices with 3mg/kg Ferumoxytol
mIP/MIP over 8 slices

Ratio of pre / post MICRO enhances vascular density

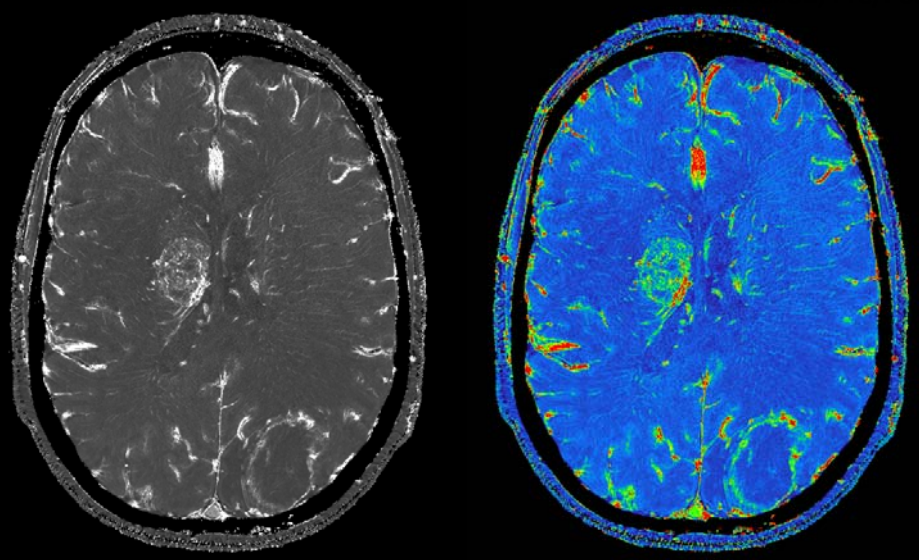

Taking the ratio of pre/post removes all background T_2* effects and basically gives an R_2* like map of the vasculature

$TE_1/TE_2/TR$ = 7.5ms/15ms/27ms; Bandwidth = 180 Hz/pxl; No. of slices = 96; Flip angle = 12°; Voxel size = 0.22×0.44×1 mm^3 ; GRAPPA = 2/36; Acquisition time for each sequence = 11 mins; Final Ferumoxytol dose = **4 mg/kg;** Dose delivery time = 21-23 mins

MICRO Imaging of Small Vessel Disease

There is an urgent need to detect damage to small vessels, especially for studying small arteries where vasculogenic neuropathology often begins.

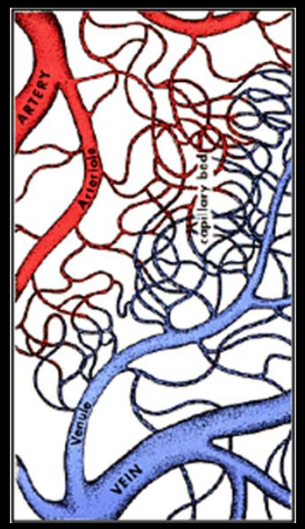

Diagrammatic
MRAV

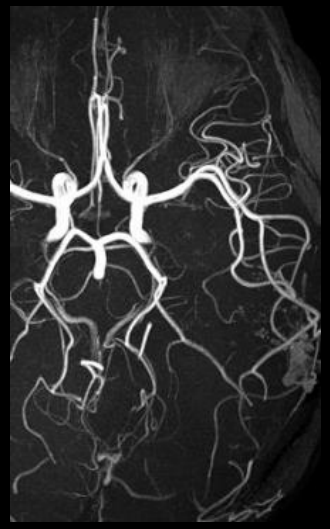

MR Arteriogram
MRA

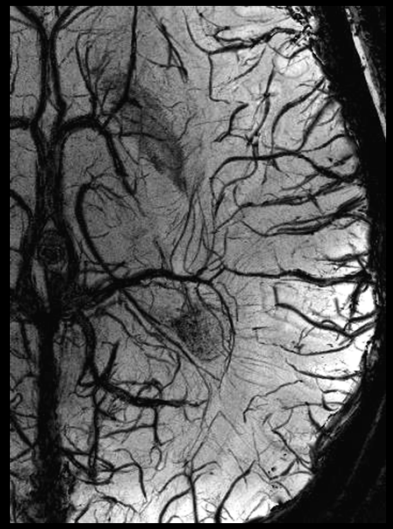

SWI Venogram
MRV

7T Images

Wrinkles in the elderly brain

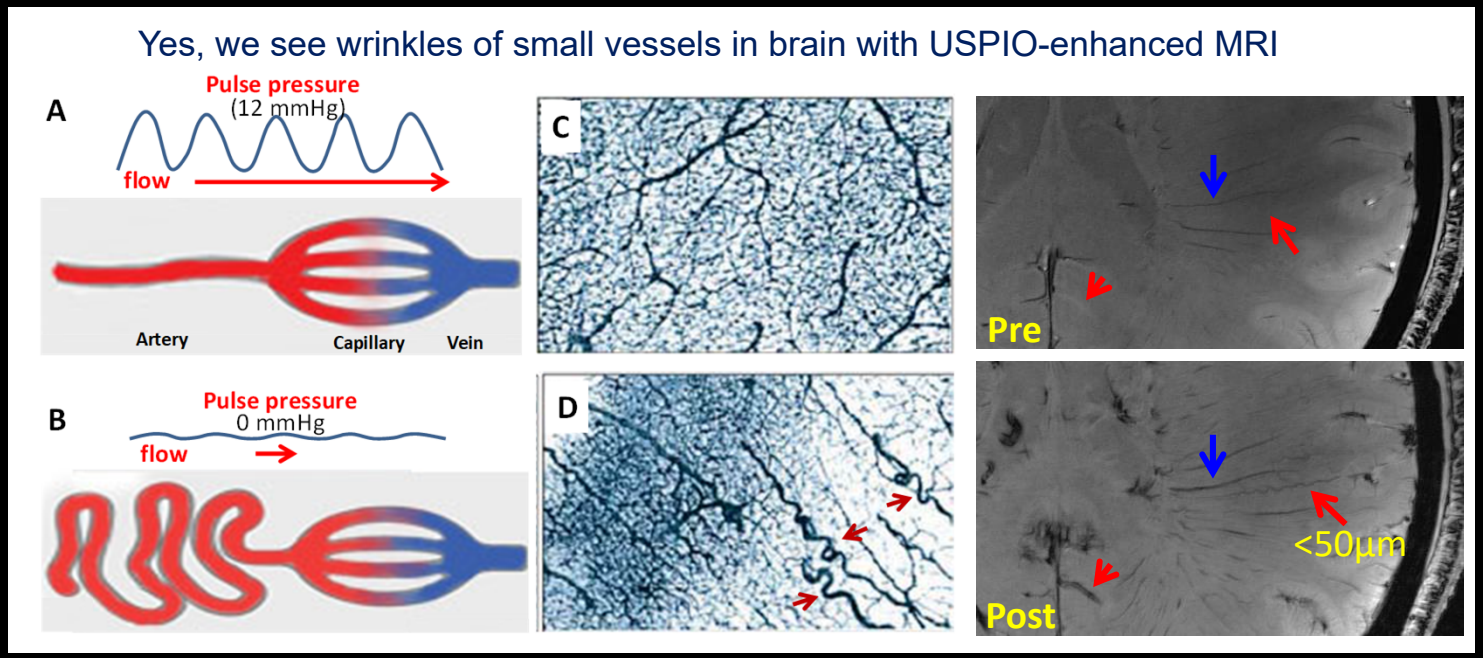

Part A and B are from Brown WR et al. Review: cerebral microvascular pathology in ageing and neurodegeneration. Neuropathol Appl Neurobiol 2011;37:56-74.

Other Avenues: In vivo MICRO imaging of the Basal Ganglia

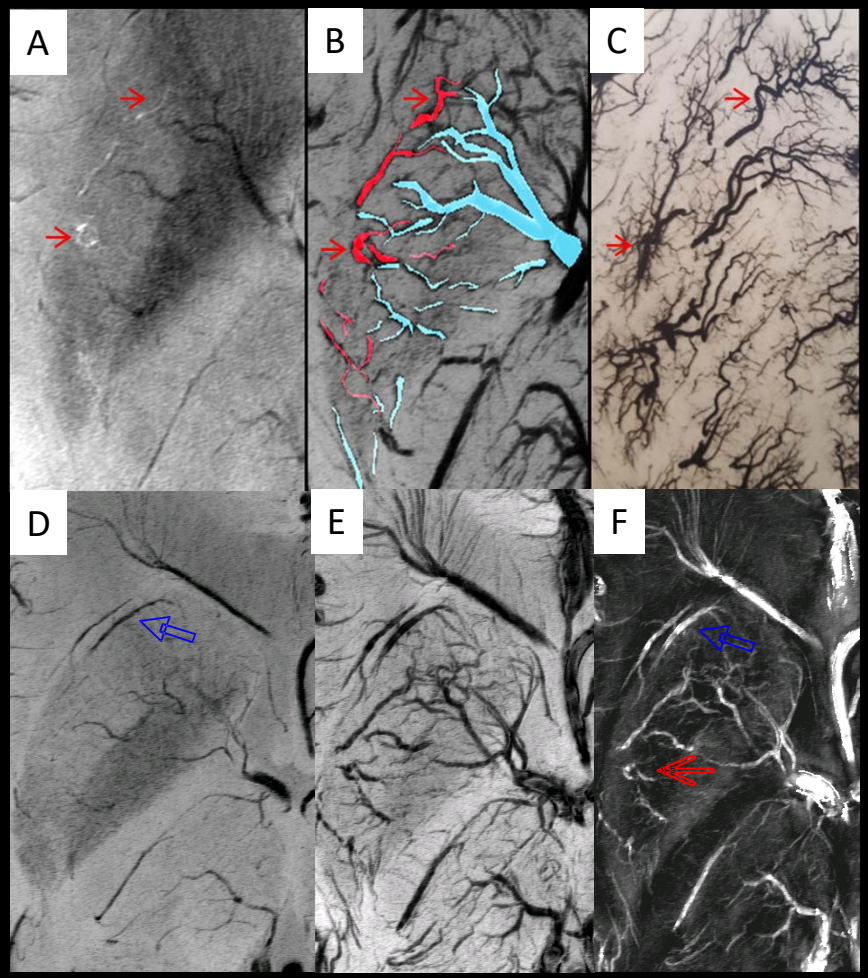

7T MICRO data with TE = 8ms and a resolution of 100µm x 200µm x 1.25mm.

(A) MIP pre-contrast magn (arteries in red).

(B) Post 4mg/kg Ferumoxytol MICRO image.

(C) Basal ganglia arteries from the cadaver brain work of Georges Salamon (1971).

(D) mIP of pre-contrast SWI (veins in blue).

(E) Post-Ferumoxytol SWI (2mg/kg) showing both veins and arteries.

(F) QSM/SWIM of veins and arteries.

Conclusions

- Imaging the microvasculature of the brain with MICRO is key to unlocking the etiology of many neurodegenerative diseases including: cancer, dementia, multiple sclerosis, stroke and traumatic brain injury
- Imaging with MICRO at 7T offers the potential to image with 250 x 250 x 1000μm^3 in a reasonable period of time with good SNR
- MICRO imaging brings us into the decade of imaging the microvasculature of the entire human body
- Lesion-pertaining vascular abnormalities were identified using MICRO data with significantly increased detectability